



Congenital Coagulation Factor XIII Deficiency Revealed by Convulsion: A Case Report

N. Mebrouk^{1*}, T. Benouachane¹, L. Chtouki¹, F. Jabourik¹ and A. Bentahila¹

¹Hôpital d'Enfants de Rabat, Morocco.

Authors' contributions

This work was carried out in collaboration among all authors. Authors NM and AB designed the study, performed the statistical analysis, wrote the protocol, wrote the first draft of the manuscript, and managed the analyses of the study. Authors NM and AB managed the literature searches. All authors read and approved the final manuscript.

Article Information

DOI: 10.9734/AJPR/2021/v6i130187

Editor(s):

- (1) Dr. Thomaz Rafael Gollop, Universidade de Sao Paulo, Brazil.
(2) Dr. Emmanouil (Manolis) Magiorkinis, General Hospital for Chest Diseases Sotiria, Greece.

Reviewers:

- (1) Rasika Setia, BLK Super Speciality Hospital, India.
(2) M. R. Franco Junior, Federal University of Uberlandia, Brazil.
Complete Peer review History: <https://www.sdiarticle4.com/review-history/69366>

Case Study

Received 02 May 2021
Accepted 08 July 2021
Published 15 July 2021

ABSTRACT

Factor XIII deficiency is a rare inherited disease, with a particularly high risk of intracerebral hemorrhage. We report the case of a newborn who was suspected to have a coagulation disorder at birth, due to an intracerebral hemorrhage. A quantitative dosage of factor XIII was requested but the usual coagulation tests (thromboplastin, thrombokinase, fibrinogen) were normal. Because of unavailability of specific treatment with factor XIII concentrate, the patient was treated with fresh frozen plasma. The initial dose was for normalizing factor XIII; subsequent monthly doses were designed for preventing the occurrence of serious bleeding.

Keywords: Intracerebral haemorrhage; factor XIII; fresh frozen plasma; pediatrics.

1. INTRODUCTION

The final step in the coagulation cascade consists in the generation of thrombin and the

transformation of soluble fibrinogen into insoluble fibrin. The factor XIII activated by thrombin makes the fibrin polymer insoluble and stable which creates a fibrin clot. Congenital

*Corresponding author: Email: nadia.mebrouk@hotmail.com;

coagulation factor XIII deficiency (fibrin stabilizing factor) is a rare hemorrhagic disease, discovered by Duckert et al. in 1960 [1]. The risk of intracranial hemorrhage is particularly high at any age, spontaneously or with minor trauma. It is associated with high morbidity and mortality, particularly in children [2].

We report a case of spontaneous intracerebral hemorrhage in a newborn baby with factor XIII deficiency, responsible for anemia, complicated by convulsion.

2. CASE REPORT

Our patient was a 15-day-old newborn baby, the only child of non-consanguineous parents. Her 35-year-old mother had a history of miscarriage at 13 weeks with amenorrhea. The pregnancy was uncomplicated, and the birth was vaginally, delivery was normal; birth weight was 3000 g, length 49 cm.

The newborn was admitted to the ward for vomiting with convulsion without fever. On admission, the newborn was pale, dehydrated with signs of intracranial hypertension, anterior bulging and beating fontanel, sunset gaze, disjunction of the cranial sutures with head circumference at 40 cm. A cerebral tomodensitometry showed multiple extra-axial collections of different density related to hematomas of different ages, multiple hypodense parenchymal lesions with spontaneously hyperdense areas which could be related to foci of edema-hemorrhagic contusion or intra-haematomas. parenchymal liquefied. (Fig. 1). Laboratory workup showed normochromic normocytic anemia with hemoglobin at 6g/dl. Average globular volume: 101.7 μ m³; average corpuscular hemoglobin content: 34.8pg; leukocytes: 14.77 10^3 / μ l; polynuclear: 3.29 10^3 / μ l. Lymphocytes: 8.7.10³ / μ l; platelets: 695 10^3 / μ l;. Ionogram: Sodium: 116 mEq / l. Potassium: 5 mEq / l; chlorine: 88 mEq / l. Alkaline reserve: 16 mEq / l. Blood sugar: 0.92g / dl. Urea: 0.2g / l. Creatinine: 3.9 mg / l. Protidemia: 60g/l.

Hemostasis assessment: Prothrombin rate at 95%, partial thromboplastin time activated at 32/30, fibrinogen at 3.4 g / L and a factor XIII (F XIII) level at 5%. In view of the cerebral hemorrhage and the results of the hemostasis assessment, the newborn hemorrhagic syndrome due to F XIII deficiency in coagulation was retained.

Faced with anemia, the newborn was transfused with red blood cells. Because of unavailability of factor XIII, brain bleeding due to factor XIII deficiency was managed by transfusion of fresh frozen plasma (PFC) at a rate of 10 ml / kg for three days, then a preventive dose (10 ml / kg) of PFC every 4 weeks. The evolution was marked by the correction of the factor XIII level, the patient's clinical condition improved dramatically, the patient no longer convulsed, the head circumference normalized.

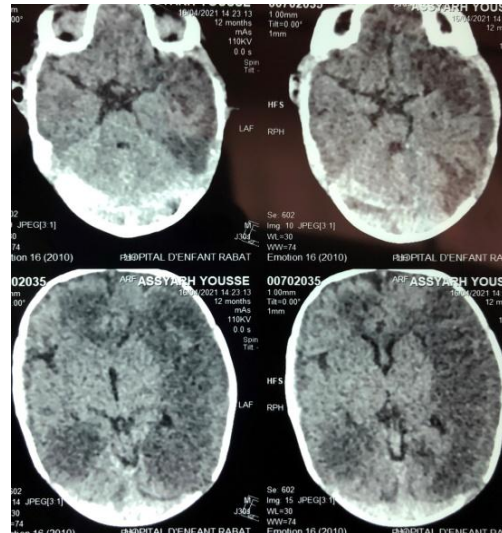


Fig. 1. A cerebral tomodensitometry with multiple haematomas

3. DISCUSSION

Congenital factor XIII (FXIII) deficit in coagulation is an exceptional hemostasis abnormality estimated to occur worldwide at one case per two million people. Currently, more than 200 cases are reported worldwide [3]. Thrombin by detaching fibrinopeptides A and B from fibrinogen allows the formation of fibrin monomers. The monomers spontaneously form a soluble polymer by linking the amino terminal ends of the α and β chains to the carboxyterminal regions of the γ and β chains of neighboring monomers. Factor XIII activated (F XIIIa) by thrombin is a transglutaminase. This enzyme catalyzes the formation of covalent bonds between lysine and glutamine residues of α and γ chains of neighboring monomers. Insoluble polymers stabilized by F XIIIa constitute the fibrin clot. The clinical phenotype results from the fragility of the fibrin clot: hemorrhage when the umbilical cord falls, this sign is neither constant nor pathognomonic, is

present in 80% of cases [2,3]. The risk of intracranial hemorrhage is particularly high (25 to 60%) at any age, spontaneously or with minor trauma [2,4]. Subcutaneous or muscular hematomas, periarticular hemorrhages, those complicating circumcision or delayed in relation to the trauma, may exist [2]. Spontaneous splenic rupture is an exceptional complication.

Diagnosis of FXIII deficit can be difficult in the absence of strong clinical suspicion [5]. Standard hemostasis tests such as prothrombin time, platelet count, fibrinogen level, and bleeding time are all normal [6]. Suspicion of a genetic defect in hemostasis should lead to assay for FXIII activity. Thus, the first case was diagnosed by measuring the solubility of the clot in urea solution [7]. This test was abandoned because it was too insensitive and too long and it is the chromogenic assay of factor XIII with Berichrom which is currently used [8]. The normal rate of FXIII ranges from 50 to 220%.

Treatment with F XIII concentrate (Fibrogammin) [7] which is obtained from fresh frozen plasma (PFC), is recommended in the event of bleeding or as a prophylactic in the event of severe deficiency, given the risk of potentially life-threatening bleeding, including cerebral-meningeal hemorrhage. The dose of F XIII to give depends on the site of bleeding. If the bleeding is moderate, the dose is 20-30 IU / Kg by intravenous injection. If the bleeding is severe, especially cerebral, the recommended dose is 50 IU / kg to be maintained for several days. For preventive treatment The recommended dose is 10 U / kg. This dose is increased to 35 U / kg in the event of surgery [9]. The spacing of the catches is explained on the one hand by the long half-life of F XIII (5 to 10 days), and on the other hand by the fact that an F XIII rate of 3 to 10% is considered sufficient to prevent spontaneous bleeding. If factor XIII concentrate is not available, a transfusion of 10 ml / kg of weight of PFC, which is also effective, ensures effective hemostasis for four to five weeks [7]. The prognosis is related to hemorrhagic sequelae (especially cerebral) in the absence of initiation of a long-term prophylaxis regimen [2,3].

4. CONCLUSION

Coagulation factor XIII deficiency is a rare abnormality that should be considered in the presence of unusual hemorrhage in the neonatal period, especially when associated with delayed healing and hemorrhage during cord fall.

Adoption of a long-term prophylaxis regimen is recommended upon diagnosis to avoid the occurrence of intracerebral hemorrhage.

CONSENT AND ETHICAL APPROVAL

As per international standard or university standard guideline patients consent and ethical approval has been collected and preserved by the authors.

ACKNOWLEDGEMENTS

We are grateful to the patient and her family for their collaboration.

COMPETING INTERESTS

Authors have declared that no competing interests exist.

REFERENCES

1. Duckert F, Jung E, Shmerling DH. A hiesto undescribed congenital hae- morrhagic diathesis probably due to fibrin stabilizing factor deficiency. *Thromb Diath Haemat* 1960;5:179-86.
2. Perez DL, Diamond EL, Castro CM, Diaz A, Buonanno F, Nogueira RG, et al. Factor XIII deficiency related reccurent spontaneous intracerebral hemor- ragie: a case and literature review. *Clin Neurol Neurosurg*. 2011;113: 142-5.
3. Medhaffar M, Elloumi M, Guermazi S, Kallel C, Mseddi S, Bellaaj H, et al. Congeni- tal factor XIII deficiency in the south of Tunisia. *Pathol Biol*. 2006;54:349-52.
4. Mannucci PM, Tuddenham EG. The hemophilias-from royal genes to gene therapy. *N Engl J Med* 2001;7:1773-9 [Review. Erratum in: *N Engl J Med*. 2001; 345-384.
5. Bader-Meunier B, Dreyfus M. Exploration of hemostasis disorders in children (excluding the neonatal period). *Arch Pediatr* 1999;6:1086-91.
6. Kobayashi T, Terao T, Kojima T, Takamatsu J, Kamiya T, Saito H. Congenital factor XIII deficiency with treatment of factor XIII concentrate and normal vaginal delivery. *Gynecol Obstet Invest* 1990;29:235-8.
7. Nugent DJ. Prophylaxis in rare coagulation disorders-factor XIII deficiency. *Thromb Res* 2006;118(Suppl.1):S23-8.
8. Diehl R, Thouvenin S, Reynaud J, Jamal-Bey K, Teyssier G, Ste' phan JL,

- et al. Factor XIII deficiency in a newborn. Arch Pediatr 2007;14:890–2.
9. Dreyfus M, Arnuti B, Beurrier P, et al. Safety and efficacy of Fibrogammin P for the treatment of patients with severe FXIII deficiency. J Thromb Haemost. 2003;1(Suppl.1):P0299.

© 2021 Mebrouk et al.; This is an Open Access article distributed under the terms of the Creative Commons Attribution License (<http://creativecommons.org/licenses/by/4.0>), which permits unrestricted use, distribution, and reproduction in any medium, provided the original work is properly cited.

Peer-review history:
The peer review history for this paper can be accessed here:
<https://www.sdiarticle4.com/review-history/69366>