



Bilateral Task-oriented Training and Strengthening Leads to Improvement in Gross Motor Functioning in Patients Post-ischemic Stroke: An Interesting Case Study

**Arasha Khan^{a#}, Rebecca Timothy^{b*†}, Pallavi Harjpal^{b‡},
Rakesh Krishna Kovala^{b§}, Mohammad Irshad Qureshi^{bΩ},
Ragini Dadgal^{b†} and Snehal Samal^{b†}**

^a *Ravi Nair Physiotherapy College, Datta Meghe Institute of Medical Sciences, Wardha, Maharashtra, India.*

^b *Department of Neuro Physiotherapy, Ravi Nair Physiotherapy College, Datta Meghe Institute of Medical Sciences, Wardha, Maharashtra, India.*

Authors' contributions

This work was carried out in collaboration among all authors. All authors read and approved the final manuscript.

Article Information

DOI: 10.9734/JPRI/2021/v33i60B34909

Open Peer Review History:

This journal follows the Advanced Open Peer Review policy. Identity of the Reviewers, Editor(s) and additional Reviewers, peer review comments, different versions of the manuscript, comments of the editors, etc are available here: <https://www.sdiarticle5.com/review-history/76815>

Case Report

Received 02 October 2021
Accepted 08 December 2021
Published 26 December 2021

ABSTRACT

Background: A stroke is a medical emergency that requires immediate attention. Early intervention can prevent brain damage and other adverse outcomes. An ischemic stroke occurs when a blood clot stops or narrows in a blood vessel that leads to the brain.

Presentation of Case: In the present case, a 63-year-old retired Zila Parishad worker came to our hospital with complaints of fever and weakness; after six days of medication and hospital stay, his fever subsided, but he developed weakness of the right upper extremity and slurring of speech. Regular investigations were done. MRI revealed Acute Infarct in the Left Frontal Region.

[#]BPT Student,

[†]Assistant Professor,

[‡] Resident,

[§]Associate Professor,

^Ω Professor and Head,

*Corresponding author: E-mail: timothyrebecca12@gmail.com;

Discussion: Bilateral training is proved to be effective in improving hand functioning in patients post-stroke. This is the application of the movement to both the extremity to gain progress.

Conclusion: The patient was provided with medical, regular physiotherapy management, and speech therapy leading to improvement in his condition. He is still under regular physiotherapy for improvement in his fine motor function.

Keywords: Acute ischemic stroke; cerebrovascular disease; rehabilitation; case report.

1. INTRODUCTION

A stroke occurs when blood flow to the brain is disrupted, resulting in a temporary loss of neurological function. Stroke is the fourth leading cause of death in adults and the leading cause of neurological disability [1]. A significant public health problem is the prevention of acute ischemic stroke. The purpose of intravenous thrombolysis and endovascular thrombectomy in insufficiently chosen individuals is to achieve recanalization and reperfusion of the ischemic penumbra [1]. It is critical to treat ischemic stroke correctly to reduce mortality and morbidity [2].

Ischemic stroke is the most common type of stroke, accounting for around 80% of all cases. It is caused by thrombus components that result in low systemic perfusion pressures. Acute ischemic stroke (AIS) is one of the most dangerous conditions that endanger human health worldwide; it causes severe disability and has a high risk of recurrence and mortality [3].

Ischemic stroke has been on the rise in young adults since the 1980s, which has coincided with an increase in the prevalence of vascular risk factors and substance abuse among this age group [4]. Ischemic strokes account for 68% of all strokes globally, with hemorrhagic strokes accounting for 32% [5-6].

The ischemic stroke can affect any of the three territories of the Cerebral artery. Here, the middle cerebral artery is affected, leading to more upper limb involvement. So, our rehabilitation focused more on improving the upper extremity function and task-oriented training to the upper limb [7].

Patients Information: A 63 years old male patient, the resident of Yavatmal, Maharashtra, who was retired from his job in 2015 as a worker of Zila Parishad, presented to Acharya Vinobha Bhave Rural Hospital with complaints of fever since 10/10/21 along with cough & cold, and weakness. He then consulted to doctor on the 11th and was on regular medication. On the 6th day, i.e., 16/10/21, he complained of development

of numbness in his right arm and had difficulty in speech, and was afebrile. The patient complained of weakness on the right side of the body, but his gait was normal. He faced problems performing movements like daily hand movements, right arm, and no strength in the wrist, and he could not hold the objects. The patient lived in a rural place and was illiterate.

Clinical Findings: The patient is conscious, cooperative, and well oriented. All the vitals were normal. During a physical examination, there was no postural abnormality. There was no superficial, profound, or cortical sensory loss. On motor examination, the tone on the right upper extremity was reduced compared to the left side; no voluntary control was there in the right wrist. There was no tonal abnormality in the lower limbs. The range of motion of the right upper limb was reduced, while the left upper limb and both lower limbs had a normal full range of activities. The Deep tendon reflexes, i.e., the biceps jerk and triceps jerk, were diminished on the right side while intact on the left upper extremity. Right-hand coordination was also impaired (Finger- nose test was positive).

Clinical Diagnosis: The patient was investigated for a routine checkup, MRI, Echo. The Echo was found to be expected. After all the investigations and the clinical findings, the patient was diagnosed with Acute Infarct in the Left Frontal Region. Age-related atrophic changes with pre ventricular ischemic changes were found.

Physiotherapy Interventions: Physiotherapy was primarily focused on strengthening of muscles of the shoulder joint. Physiotherapy care was provided once a day, which includes passive, active-assisted, and strengthening exercises to the upper limb of the right side. For strengthening, the protocol was ten repetitions of 3 sets with two minutes of rest between the sets. It started with 1kg of weight, progressing to 2kg by the next 15 days. Bilateral training was focused [8]. The patient was given the exercises to the affected side within the pain-free limit to

the full range of motion. The patient was asked to actively perform movements of the shoulder joint where possible and was assisted where there was no or less muscle power [9] For the recovery of the wrist curls, rubber band strengtheners, wrist strengtheners improve strength and power in the wrist, forearm, and fingers [10].

Table 1. Timeline of events

Date of visit to the hospital	10/10/2021
Date of start of physiotherapy	17/10/2021
Last date of rehabilitation	01/12/2021

Table 2. Outcome measures

Outcome Measures	Pre- Rehabilitation	Post-Rehabilitation
MAS (Modified Ashworth Scale)	Grade 1	Grade 0
Brunnstrom stage	Stage 0	Stage 5
Fugl-Mayer Assessment (Upper extremity)	10	27
FIM (Functional Independence Measure)	84	105



Fig. 1. POSTURE: Standing

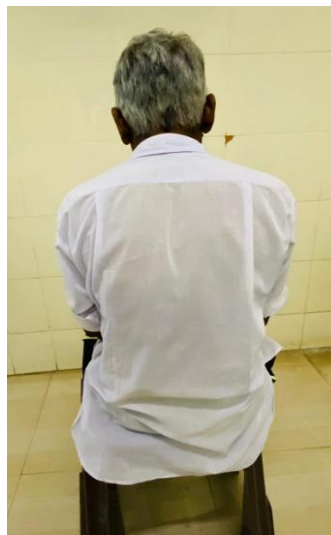

Fig. 2. POSTURE: Sitting

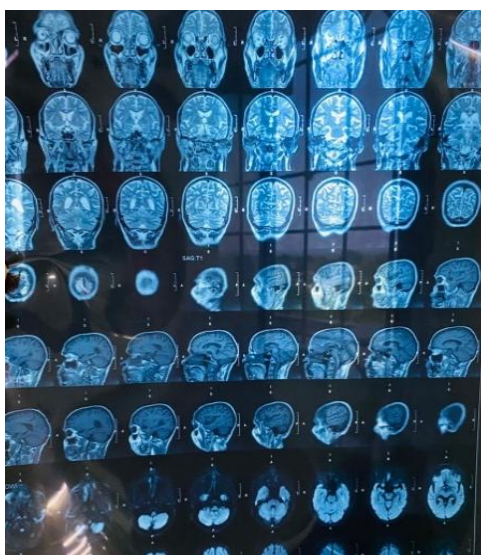


Fig. 3. MRI findings of patient

2. RESULTS

This patient received a normal range of motion exercises and strength training for the upper extremity. He received a proper strengthening protocol and got a tremendous improvement in the gross motor function, but the affection in fine motor function is still under rehabilitation. We achieved the expected recovery in 2-3 weeks.

3. DISCUSSION

This case study mainly focused on improving patients' hand function with hemiplegia. Previous literature suggests improved hand function post physiotherapy; the focus was bilateral upper extremity training, leading to enhanced fine and gross motor functions [11]. Rigorous inpatient physiotherapy leads to an early return in role post-ischemic stroke [12].

4. CONCLUSION

Bilateral upper extremity training leads to early improvement in gross motor function of a patient, but the fine motor functions show late recovery. Most interventions focus on strengthening in the early phase affect stroke survivors' gross motor functioning.

CONSENT

A proper informed consent was taken from the patient prior.

ETHICAL APPROVAL

As per international standard or university standard written ethical approval has been collected and preserved by the author(s).

COMPETING INTERESTS

Authors have declared that no competing interests exist.

REFERENCES

1. Hurford R, Sekhar A, Hughes TAT, Muir KW. Diagnosis and management of acute ischaemic stroke. *Pract Neurol.* 2020; 20(4):304–16.
2. Herpich F, Rincon F. Management of Acute Ischemic Stroke. *Crit Care Med.* 2020;48(11):1654–63.
3. Qiu S, Xu Y. Guidelines for Acute Ischemic Stroke Treatment. *Neurosci Bull.* 2020; 36(10):1229–32.
4. Putaala J. Ischemic Stroke in Young Adults. *Contin Minneap Minn.* 2020;26(2): 386–414.
5. Chugh C. Acute Ischemic Stroke: Management Approach. *Indian J Crit Care Med Peer-Rev Off Publ Indian Soc Crit Care Med.* 2019;23(Suppl 2):S140–6.
6. Agrawal A, Joharapurkar SR, Gharde P. Ischemic stroke in a child mistaken as functional disorder. *Clin Neurol Neurosurg.* 2007;109(10):876–9.

7. Recommendations for the Early Management of Acute Ischemic Stroke: A Consensus Statement for Healthcare Professionals from the Indian Stroke Association - Dheeraj Khurana, M. Vasantha Padma, Rohit Bhatia, Subhash Kaul, Jeyaraj Pandian, PN. Sylaja, Deepak Arjundas, Ashok Uppal, VG. Pradeep, Vinit Suri D. Nagaraja, Anand Alurkar, Sunil Narayan. 2018 [Internet]. [cited 2021 Jan 25]. Available: <https://journals.sagepub.com/doi/abs/10.1177/2516608518777935>
8. Harjpal P, Qureshi MI. Efficacy of bilateral lower limb training over unilateral to re-educate balance and walking in post stroke survivors: a protocol for randomized clinical trial [Internet]. Protocol Exchange; 2021 May [cited 2021 Aug 2]. Available: <https://protocolexchange.researchsquare.com/article/pex-1497/v1>
9. Whittall J, McCombe Waller S, Sorkin JD, Forrester LW, Macko RF, Hanley DF, et al. Bilateral and Unilateral Arm Training Improve Motor Function Through Differing Neuroplastic Mechanisms: A Single-Blinded Randomized Controlled Trial. *Neurorehabil Neural Repair*. 2011;25(2): 118–29.
10. Phansopkar P, Athawale V, Birellwar A, Naqvi W, Kamble S. Post-operative rehabilitation in a traumatic rare radial nerve palsy managed with tendon transfers: a case report. *Pan Afr Med J* [Internet]. 2020; [cited 2021 Oct 22];36(141). Available: <https://www.panafrican-med-journal.com/content/article/36/141/full>
11. Rubinstein-Taybi syndrome: a rare case report of a female child emphasizing physiotherapy on gross motor function [Internet]. [cited 2021 Oct 22]. Available: <https://www.panafrican-med-journal.com/content/article/40/85/full/>
12. Physical Rehabilitation, Susan B. O'Sullivan, Thomas J. Schmitz, George D. Fulk Page No; 592,593.

© 2021 Khan et al.; This is an Open Access article distributed under the terms of the Creative Commons Attribution License (<http://creativecommons.org/licenses/by/4.0>), which permits unrestricted use, distribution, and reproduction in any medium, provided the original work is properly cited.

Peer-review history:

The peer review history for this paper can be accessed here:
<https://www.sdiarticle5.com/review-history/76815>