



Collagen-Chitosan Composite Powder as a Novel Biomaterial for Chronic Wounds in Hansen Disease-A Clinical Study

**Pombala Suresh Babu^{1*}, Harini Srinivasan², B. Sai Dhandapani³
and C. Rose¹**

¹CSIR Central Leather Research Institute, Sardar Patel Road, Adyar, Chennai 600020, India.

²Department of Statistics, University of Madras, Chepauk campus, Chennai 600005, India.

³Department of Surgery, Southern Railway Headquarters Hospital, Constable Road, Ayanavaram, Chennai 600023, India.

Authors' contributions

This work was carried out in collaboration among all authors. Author PSB designed the study, performed the study, wrote the protocol, and wrote the first draft of the manuscript. Author HS performed the statistical work of the study. Author BSD helped with the human ethical committee approval. Author CR provided guidance for the work. All authors read and approved the final manuscript

Article Information

DOI: 10.9734/JPRI/2021/v33i49B33352

Editor(s):

(1) Syed A. A. Rizvi, Nova Southeastern University, USA.

Reviewers:

(1) Jacqueline Maisonnave, Universidad de la Republica, Uruguay.

(2) Shumez Hameedullah, Al Nahil Int'l Clinic, Kuwait.

Complete Peer review History: <https://www.sdiarticle4.com/review-history/77035>

Original Research Article

Received 04 September 2021

Accepted 08 November 2021

Published 12 November 2021

ABSTRACT

Aims: Natural biomaterials are more suitable than synthetic biomaterials for in vivo applications for treating damaged tissues. Collagen and chitosan are abundantly available natural biomaterials for wound dressings for tissue/wound repair. In this context, collagen-chitosan composite powder has been used to treat chronic wounds in Hansen disease (HD) patients.

Place and Duration of Study: CSIR Central Leather Research Institute, Sardar Patel Road, Adyar, Chennai 600021, Southern Railway Headquarters Hospital, Constable Road, Ayanavaram, Chennai 600023, and Gremaltes Hospital, India between June 2013 and July 2020.

Methodology: Collagen extracted from bovine rumen, a waste product of meat industry, and a commercially available chitosan were prepared as a composite powder (COL/CS) and applied to

chronic wounds in HD patients after debridement and the wound contours were measured by planimetry. Biochemical parameters in blood samples were periodically assessed. Histopathology of wound tissue with Hematoxylin and Eosin and Masson's Trichrome staining was studied. Matrix Metalloproteinase-9 (MMP9) levels before and after treatment were estimated.

Results: Wound healing of 64.2% was obtained with COL/CS treatment and formation of granulation cells was observed early. Hemogram studies have been reported in a regression model with 95% confidence intervals. Histopathology revealed dense collagen fibres and continuity of sub-epithelial layer on 8th day. MMP-9 levels showed collagen integrity after treatment.

Conclusion: The novel biocompatible, biodegradable COL/CS wound dressing is a promising biomaterial for management of chronic wounds in Hansen disease patients.

Keywords: Chitosan; collagen; chronic wounds; hansen disease; wound dressing.

1. INTRODUCTION

With the advent of tissue engineering and regeneration over the past three decades, the use of biomaterials and natural tissue-like implants have gained immense significance for several kinds of biomedical applications. Biomaterials, natural and synthetic, have been synthesized or processed, either as a single biomaterial or a composite of two or more biomaterials for applications in wound healing, surgical implants, bone regeneration, tissue re-organization by matrix formation, tissue engineering and therapeutic delivery. For many years, researchers have attempted to construct a variety of materials in constituting substitutes for damaged, diseased or injured portions of the body. Materials such as synthetic polymers, natural macromolecules, ceramics and metals have been used as implants and grafts. The properties that make one biomaterial for a given application could prevent in being functional in another application. Hence, there is a constant need for development of various biomaterials with beneficial characteristics suitable for specific kinds of applications.

Natural biomaterials are often advantageous than synthetic biomaterials for in vivo applications because of their facile absorption, non-toxicity, poor immunogenicity, little or no antigenicity, high tensile strength, biocompatibility and biodegradability due to which they mimic the natural tissues/organs of the physiological system [1]. Collagen, a structural protein in the connective tissues of animal origin, is an abundantly available natural biomaterial with inherent desirable properties. Collagen is a hydrophilic and a hemostatic biopolymer and is an extremely good substrate for cell adhesion and cell proliferation at the tissue site [2]. Collagenous biomaterials can be prepared in different forms as powder, solution,

gel, fibre, sponge, film, sheet etc. However, pure collagen is difficult to sterilize, requires high costs of production and is susceptible to microbial infections [3]. Further, pure collagen lacks structural stability and mechanical strength upon hydration which limits its applications as structural scaffolds [4]. This necessitates the incorporation of other materials to the native collagen to achieve better scaffolding properties. Considering this, chitosan, a deacetylated form of collagen and a natural biopolymer has been crosslinked with collagen to result in a stable scaffold with desirable properties as a biomaterial composite with mechanical stability and similar biological properties [2,3,5-7]. Moreover, chitosan has several advantages as a structural and biological biomaterial to promote hemostasis, anti-inflammation, platelet adhesion and aggregation, inhibit fibrinolysis, in the proliferation of granulation in wound tissues and as an antimicrobial agent [8]. The applications of collagen (COL), chitosan (CS) biomaterials in wound healing are innumerable and COL/CS biomaterial has recently received potential significance as a promising candidate for wound healing [2,7-9].

Wound is an impairment of the skin tissue and causes infection, inflammation, loss of body fluids, electrolytes and nutrients [10,11] and disruption of blood supply, angiogenesis and matrix turnover [12] and further, causes pain, trauma and psychological breakdown of the individual. This requires clinical attention to restore skin function by healing the wounded region [13]. Normal wound healing is an orchestrated, overlapping events of hemostasis, inflammation, cell migration and proliferation and tissue remodeling which must occur in a proper sequence and a specified time [14]. Impaired wound healing occurs as a result of several diseases causing failure of acute or chronic wounds to heal in a specified manner classified

as non-healing wounds. Chronic wounds often lead to ulcer formation with uncoordinated healing process [14]. Therefore, focus on increasing the rate of wound healing is of utmost concern and is addressed by many researchers worldwide. Wound dressings which are hemostatic, anti-infective and exhibiting histocompatibility are mostly used by clinicians to promote wound healing [13]. In addition, wound dressings should reduce healing time, have no side effects and improve bioavailability [15]. Recently, Santhanam et al [16] have reviewed that bovine collagen is considered as a good source of natural collagen and can be used as a potential dressing in wound care management.

In the above context, the aim of the study was to prepare a COL/CS biomaterial from bovine source for the treatment of chronic wounds in Hansen disease (HD) patients. Patient selections were done randomly and treated in the hospital as in-patients and discharged after complete healing as per study protocol. Use of COL/CS powder as a wound dressing biomaterial for treatment of chronic wounds in HD patients is a first report investigated so far.

2. MATERIALS AND METHODS

2.1 SUBJECTS

Ethical clearance and approval was obtained from Human Ethics Committee, Southern Railway Head Quarter Hospital, Perambur, Chennai, India. The proposal for conducting human clinical study was scrutinized and approved with the Approval No. SRHQH/EC 08112014. Human in-patient subjects ($n=81$) at Gremaltes Hospital, Chennai, India, were treated according to standard clinical guidelines. The hospital is involved in control of Hansen disease (HD) and tuberculosis in the community by providing appropriate treatment. Informed consents from the patients with Hansen's disease were obtained prior to clinical investigations and observations. Appropriate controls were represented from non-Hansen disease patients (NHD). The study was performed according to the Declaration of Helsinki.

2.2 Preparation of Collagen Forms

Bovine rumen is an inedible waste of meat industry. The rumen tissue can be used as a source of collagen to produce biocompatible

materials for clinical application. Collagen was extracted from bovine rumen obtained from local abattoir and prepared as a film (COL-F) according to Shankar et al [5]. Collagen powder was prepared by cutting the collagen film into a small bits < 0.5 cm by using sterilized scissors in a cold room and ground in a mixer grinder to a fine powder. A constant temperature of 10-12°C was maintained throughout the process. Chitosan (80% deacetylated), was purchased from Sigma Aldrich (St. Louis, MO, USA). 3 g of wet collagen paste and 1 g of chitosan were blended and prepared as a cream according to the method of Udhayakumar et al [17].

2.3 Preparation of Collagen-chitosan Composite Powder

Collagen powder and the commercial chitosan were mixed in the ratio of 10:1 (w/w) and the mixture is referred as collagen/chitosan powder COL/CS. Sterilization of COL/CS was carried out by Ethylene oxide 'ETO' gas.

2.4 Clinical Study

Patients with Hansen's disease (HD) were identified and included in the study. Their personal data, clinical data and past and present history were recorded. Deep (sinus) wounds were treated with collagen cream as these wounds cannot be penetrated by COL/CS powder, while, plantar and chronic wounds (Static) were treated with the COL/CS powder. Wound cleaning and debridement was done prior to the application of biomaterial. The wounds were photographed every 4th day and the wound contours were measured by planimetry. Wound dressings were done at intervals of four days. In this study, chronic wounds including amputations were also used as subjects of treatment. Post treatment, wounds were periodically monitored and the wound contour sizes were recorded. In a representative control, a patient was treated with T-Bact ointment. The ointment was applied on the wound and compared with the experimental wound. It was observed that some wounds were foul-smelling with profuse discharge. Hence, the wound samples were tested for microbial culture and sensitivity. Hemogram parameters of the patients' blood samples before and after the application of COL/CS on Day 0 (before biomaterial application), Day 8 (on 8th day of treatment) and Day D (day of patient discharge) were assessed. All the in-patients of the study were accommodated in clean and aseptic wards

and were restricted from administering antibiotics of any type, in order to observe the effect of the biomaterial.

2.5 Microbial Infection Study

Representative male and female HD patients were included in this study. To test microbial infection, their wound samples were swabbed for identification of microbial culture, estimation of growth; and its sensitivity to several antibiotics as per standard procedures.

2.6 Planimetry

Wound size measurement was done by planimetry method. The wound contour was traced by marking the boundary of the wound in a tracing sheet. This figure was then plotted on a graph paper and the size of the wound was calculated in square cm.

2.7 Histopathological Examination

Skin samples were fixed in 10% (v/v) buffered formalin solution, embedded in paraffin wax and sectioned into 5µm thickness using a microtome. The sectioned tissues were subjected to hematoxylin and eosin (H&E) staining and Masson's Trichrome stain (collagen stain). Skin sample of NHD patient was used as control. All slides were viewed under a Nikon Eclipse E600 microscope. The skin tissue profile and matrix formation before and after treatment were observed.

2.8 Biochemical Analysis

Blood samples were drawn from the HD patients ($n=81$) before and after treatment on Day 0, Day 8 and Day D. Serum analysis of HD patients treated with COL/CS products such as cream and powder were investigated. COL/CS sheets were used in few patients ($n<5$). The biomaterial dressings were made on the 3rd and 7th day. Allergic and non-allergic patients were categorized and allergic patients were excluded from the study. Blood sugar, Complete blood count (CBC) with Erythrocyte sedimentation rate (ESR) at 30 min. and 60 min., hemoglobin (Hb), blood urea, creatinine and serum proteins profiles were regularly tested in a pathology laboratory.

2.9 Estimation of MMP9

Matrix metalloproteinase-9 (MMP9) levels in the blood plasma samples of 27 subjects with HD

before and after treatment with the COL/CS powder on Day 0, Day 8, Day D were measured using a 'sandwich' ELISA assay kit (Calbiochem TM, QIA 63).The MMP9 assay was done according to the manufacturer's guidelines given with the assay kit. In brief, the samples were incubated for 2 h with a biotinylated detector monoclonal antibody. In this period of incubation, any MMP9/biotinylated antibody complex binds to the capture antibody. Unbound antibodies in the samples were washed away. Then horseradish peroxidase (HRP)-conjugated streptavidin was mixed, which binds to the biotin label on the detector antibody. The enzyme catalyzed the conversion of chromogenic substrate tetra-methylbenzidine from a colorless to a blue solution (or yellow after the addition of stopping reagent). The intensity is proportional to the amount of MMP9 present in the sample. The colored intensity of the sample was quantified at 450 nm using a spectrophotometer instrument.

2.10 Clinical Study of Wound Dressing In HD Patients

Photographs of the HD patients' feet before and after applications of wound dressings were taken on Day 0 and on the Day of discharge.

2.11 Statistical Analysis

Statistical analysis of the hemogram data showed that regression model was significant. Correlation study of the linear relationship between two variables and their association has been carried out for personal and clinical datasets.

3. RESULTS AND DISCUSSION

Bovine collagen is a promising resource of collagen biomaterial [16]. Chitosan has several inherent advantages [8] and can be crosslinked with collagen for various kinds of applications [2,7]. The use of biomaterials in wound healing has been studied as wound care is a major cause of concern for many years [7,12,13,18-20]. Hansen's disease (HD), renamed from leprosy, requires particular attention in the treatment of wounds due to impairment of wound healing process leading to chronic wounds which can further result in severe ulceration and an uncoordinated healing process. HD wounds, classified as non-healing wounds are difficult to manage causing disability of the patient and costs of treatment is very high [21]. HD wounds are unrecognized clinical problems [22]

associated with several comorbidities [23]. A successful treatment protocol is therefore required for such hard-to-heal chronic ulcers in HD patients using collagen biomaterials. We have prepared a collagen-chitosan (COL/CS) powder for application as wound dressing to treat chronic wounds in HD patients as an alternative to conventional amniotic membrane.

3.1 Wound Microbial Culture Analysis

The wound cells (pus cells) show severe microbial infection upon culture and the microorganisms cultured were both Gram positive and Gram negative. *Pseudomonas* sp. and *Staphylococcus* sp. are identified and there is considerably significant growth of both organisms. The sensitivity of these *Bacilli* to different antibiotics are been shown in Table 1. Microbial infection was very high in the wound (pus) cells due to the severity of the wound indicating chronic ulceration and the antibiotic sensitivity profile shows that the isolated bacteria were sensitive to few antibiotics and were resistant to several antibiotics and that antimicrobial action alone cannot suffice wound treatment.

3.2 Histopathology Studies

The control tissue specimen shows irregular acanthosis and marked pseudoepitheliomatous hyperplasia (Fig. 1a). The sub-epithelial layer appears edematous. Chronic inflammation in the granulation tissue is observed. Irregular and diffuse distribution of collagen is seen. There is no evidence of histiocytic infiltrates or granulomas. Skin with marked acanthosis, marked hyperkeratosis and parakeratosis is observed in the test specimen (Fig.1b). Sub-epithelium shows dense collagen deposition with minimal granulation tissue formation. Only a mild inflammation is observed. There is no evidence of any granulomas. COL/CS powder has been used as wound dressing and observed for clinical changes that could effect proper wound healing. Histopathology of the wound before application of COL/CS show diffuse collagen matrix and discontinuous sub-epithelium layer with lack of formation of collagen at wound site. Chronic inflammation could result from mechanical movement of cells to the wound site. After applications of COL/CS, dense collagen formation and continuous sub-epithelium layer were observed. This clearly reveals that the biomaterial has induced collagen formation. COL/CS composite has the ability to initiate

fibroblastic activity at the wound site. The deposition of granulation tissue at the wound site employs neutrophils, macrophages and leucocytes to stop inflammation. With COL/CS composite, chitosan can show healing properties due to binding with red blood corpuscles and its antibacterial activity, while, collagen can support cell growth and tissue growth [24]. Chitosan depolymerizes during wound healing and releases N-Acetylglucosamine [25] which can promote fibroblast proliferation and collagen deposition [26]. Mature collagen deposition observed from Masson's trichrome staining show that the wound is progressing towards remodeling phase [27]. Formation of granulation tissue is important in skin repair because of its capacity to refill wounded cells and promote epidermal regeneration [8]. Wound healing property by histopathological studies show biocompatibility of COL/CS biomaterial [7].

3.3 Wound Healing Study

Fig.1c shows the effect of COL/CS on the size of the wound at time of admission (size 0) and discharge (size D). The average size of the wound while admission was 6.36 cm² and it significantly reduced to an average of 2.28 cm² during discharge. Meanwhile, for the control with application of T-Bact, the average size of the wound while admission was 6.78 cm² and it reduced to an average of 3.69 cm² during discharge. The study of wound size over a duration of 28 days is depicted in Fig.1d.

Both limbs of the patient were included in the study. Initial size of the wound in the right limb was measured as 4 cm². On the left limb the patient had another wound of size 1.96cm². The wound in the left limb was treated as control and the right limb wound was treated with COL/CS. On the 14th day the wound size was recorded. The size of the control wound reduced to 1.54cm² from 1.96cm² and the size of the wound treated with COL/CS powder reduced to 2.7cm² from 4 cm². On the 28th day the wound sizes were recorded again and the control wound reduced to 0.88cm² and the wound treated with COL/CS reduced to 0.4 cm². About 45.6 % wound closure was obtained in the representative control, while, 64.2% wound closure was observed in COL/CS treated wounds on the 28th day.

Measurement of wound size is a very important factor in the process of wound healing. Chronic plantar ulcers are a manifestation of Hansen's

disease and are hard-to heal wounds [21]. In such patients, the demand for new and efficient wound dressings seems to be critical. Planimetry studies clearly indicate the efficacy of COL/CS as a wound healing material. The COL/CS biomaterial has a significant effect on the size of the wound when discharged (Size D) for all the patients. It was found that >50 % of the wound contour was healed within the period of three days and wound contraction and granulation is significantly noted. Most of the wounds treated with the wound dressing responded well with progressive healing, with the exception of few patients showing poor healing results. The prolonged healing time can be attributed to the higher levels of underlying infection wounds.

3.4 Biochemical Analysis

Blood plasma samples tested for biochemical parameters on Day 0, Day 8 and Day D have been statistically represented in Table 2. Before proceeding to model building, variable selection has been made using backward elimination procedure. It has been found from the final step that some variables were excluded at the final step: Total protein on Day 8, Day D, A/G ratio on Day 8, Day D, Basophils count on Day 8, the number of dressings, creatinine levels on Day 0, Day 8 and Day D, Urea on Day 0, Day 8, Day D, Hypertension, Age, Recurrence, Color and Diabetes. These variables have been excluded from the study and the statistical model has been built. The dependent variable was the COL/CS wound dressing and the rest of the parameters were assigned as predictors. By ANOVA, the Regression model has been considered to be significant. The association between COL/CS and other descriptive variables has been studied by the regression model. Only the associated variables in the hemogram study have been indicated in Table 2. ESR on Day 8 (30 min), ESR on Day D (30 min), ESR on Day 0 (60 min), ESR on Day 8 (60 min), ESR on Day D (60 min), Hb on Day 0, Hb on Day 8, RBC on Day 0, RBC on Day 8, Neutrophils count on Day 0, Lymphocytes count on Day 0, Monocytes count on Day 0, Neutrophils count on Day 8, Eosinophils count on Day 8, Monocytes count on Day 8, Eosinophils count on Day D, Lymphocytes count on Day D, Albumin count on Day D, Globulin count on Day D were all found to be significant and associated with COL/CS. The variation in the blood plasma profiles provides valuable biochemical insights of the efficacy of wound dressing on the biochemical levels of the HD patients. From the statistical data, regression

method of analysis is appropriate for the biochemical parameters. Some hemogram parameters have been excluded in the analysis. It can be seen that ESR levels at 30 min and 60 min were very significant due to chronic inflammation, as ESR is considered to be an inflammatory marker. From the blood counts, lymphocytes and monocytes were significant, to act as the first line of defense on the prevalent inflammation. These data suggest that inflammation is an important factor for healing of chronic wounds in HD patients. Albumin and globulins, the major serum proteins showed significance values on Day D demonstrating healing efficiency of the dressing biomaterial.

Correlation analysis of the linear relationship among the personal and clinical variables have been shown in Fig.2. The datasets (variables) analysed show that there is a strong positive relationship between smoking and sex, occupation and non-smoker, smoking and tobacco and diabetes and hypertension. Some of the variables showed negative correlation. By correlation analysis of personal and clinical variables, good correlation was obtained between the associated variables while some of them exhibited negative correlation. These data show that association between variables is important as comorbidities have been reported as risk factors in delayed wound healing [23].

3.5 Expression of MMP9

The concentration of MMPs in the samples collected from the patients on Day 0, Day 8 and Day D (complete healing and discharge) have been shown in Fig.3. The lowest value of MMP9 concentration was recorded to be 0.349 ng/ml on Day D and highest value was 10.442 ng/ml on Day 8. As seen in the figure, the patient (representative case 1) in the order of 10th place exhibited elevated concentration of MMP9 compared to other patients' values. This elevation was observed on Day 8 which could be due to wound physiological condition during treatment. However, the peak concentration was not maintained and suddenly reduced to normal followed by subsequent COL/CS application. Wound cells express distinct patterns of Matrix metalloproteinases (MMPs) in their environment which are diverse and involved in extracellular matrix (ECM) turnover [28] and in the wound healing process [29]. MMP9 expression in wound fluid is related to the clinical severity of ulcers [30]. Hence, regulation of expression of MMPs can improve wound healing

[29]. Therefore, we have studied the expression of MMP9 on Day 0, Day 8 and Day D in HD patients. The MMP9 assay results reveal significant reduction of MMP9 level in the sample with respect to time. On day 0 (the day of sample collection) the concentration was very high compared to normal range in all the patients. On day 8 the MMP9 concentration was considerably lowered due to the action of COL/CS composite. The data clearly show that the application of COL/CS composite significantly reduced the MMP9 levels on Day D. The MMP9 enzyme binds with the composite, degrades the material, and thereby newly synthesized collagen is freed from the proteolytic process. According to our MMP9 assay results, it is demonstrated that the

COL/CS biomaterials on wound notably reduced the MMP9 activity.

3.6 Case Study

In a case study, the photographs of chronic wounds of a HD patients on Day 0 and after treatment on Day D have been shown in Figs.4& 5. The image on Day 0 shows chronic ulceration of the wounds (4a,b,c) (5 a,b). On the day of discharge, after consecutive dressings, the images show improved healing of the wounds (4d,e,f) (5 c,d).Healing patterns in case study of HD patients after 8 days of wound dressing confirms the wound healing ability of COL/CS biomaterial. The severity of ulcers is significantly reduced after treatment.

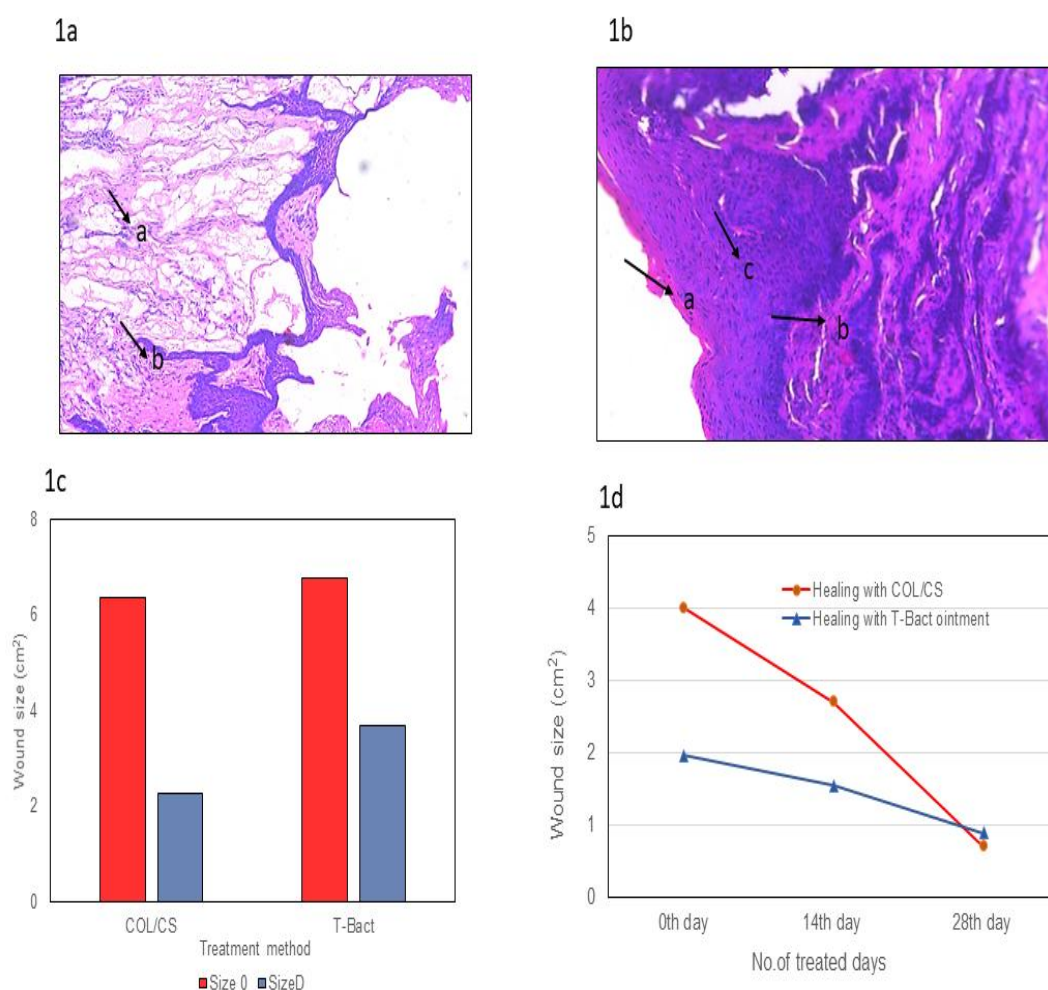


Fig. 1. Histopathological staining of untreated (1a) and treated (b) skin tissue. Diffuse collagen (a) and chronic inflammation (b) can be observed in 1a and continuous sub-epithelium (a); formation of collagen fibres (b) and new granulation tissue (c) can be observed in 1b images. Mean values of wound size measurements on Day 0 and Day D (1c) and up to 28 days (1d) were recorded by Planimetry

Table 1. Antibiotic sensitivity profiles of *Pseudomonas* and *Staphylococcus* sp.

Microorganism	Highly sensitive	Sensitive	Resistant
<i>Pseudomonas</i> sp.	Ofloxacin	Streptomycin	Tetracycline
	Azithromycin	Chloramphenicol	Doxycycline
	Cefazolin	Penicillin-G	Ciprofloxacin
	Cefixime	Cephotaxime	Kanamycin
		Co-trimoxazole	Amoxycillin
		Amikacin	Levofloxacin
		Cefdinir	Norfloxacin
		Ceftazidime	Aztreonam
			Clarithromycin
			Cefuroxime
			Erythromycin
			Cephalexin
			Cefepime
<i>Staphylococcus</i> sp.	Tetracycline	Amoxy-Clavulanic acid	Ofloxacin
	Ceftriaxone	Cefuroxime	Gentamycin
	Co-trimoxazole	Cefixime	Doxycycline
	Cephotaxime	Erythromycin	Kanamycin
	Aztreonam	Chloramphenicol	Amikacin
	Ceftazidime	Penicillin-G	Ampicillin
			Cefdinir
			Nalidixic acid
			Azithromycin
			Levofloxacin
			Ciprofloxacin
			Cephalexin
			Cefazolin
		Norfloxacin	

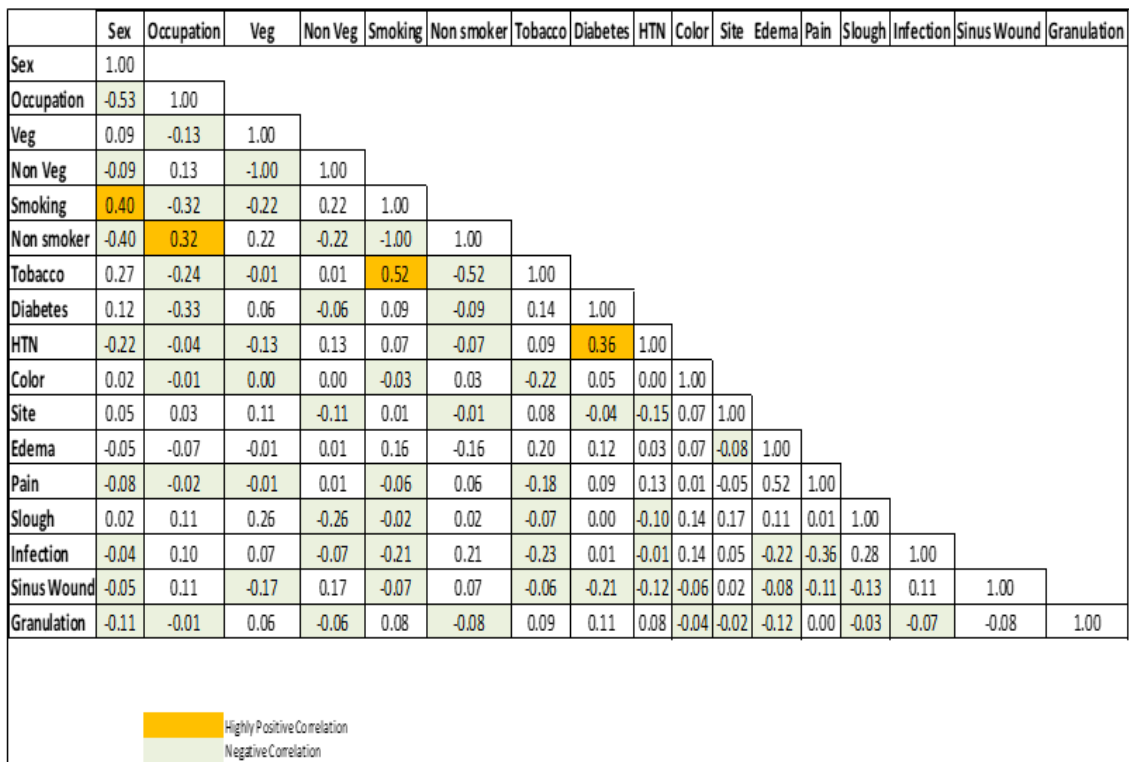


Fig. 2. Correlation analysis of personal and clinical variables of HD patients showing strong positive relationship

Table 2. Regression Model analysis of hemogram parameters of HD patients before and after treatment with COL/CS composite powder

Hemogram parameter	Day of treatment	B	Std. Error	t-value	Significance	95.0% Confidence Interval for B	
						Lower Bound	Upper Bound
ESR 30 min	^b 0	0.013	0.007	1.897	0.070	-0.001	0.027
	^c 8	-0.008	0.003	-2.256	0.034	-0.015	-0.001
	^d D	-0.019	0.009	-2.177	0.040	-0.036	-0.001
ESR 60 min	0	-0.015	0.007	-2.110	0.046	-0.030	0.000
	8	0.007	0.003	2.090	0.048	0.000	0.014
	D	0.012	0.005	2.253	0.034	0.001	0.023
Hemoglobin	0	0.285	0.079	3.605	0.001	0.122	0.449
	8	-0.342	0.106	-3.230	0.004	-0.560	-0.123
	D	-0.073	0.073	-0.993	0.331	-0.224	0.079
RBC	0	0.244	0.110	2.212	0.037	0.016	0.472
	8	-0.398	0.186	-2.140	0.043	-0.783	-0.013
	D	0.185	0.104	1.774	0.089	-0.031	0.400
Neutrophils	0	-0.073	0.025	-2.960	0.007	-0.123	-0.022
	8	0.052	0.021	2.459	0.022	0.008	0.096
	D	0.017	0.015	1.113	0.277	-0.014	0.047
Eosinophils	0	-0.041	0.039	-1.049	0.305	-0.122	0.040
	8	0.184	0.062	2.948	0.007	0.055	0.312
	D	-0.114	0.046	-2.457	0.022	-0.210	-0.018
Lymphocytes	0	-0.090	0.027	-3.298	0.003	-0.146	-0.033
	8	0.014	0.018	0.774	0.447	-0.023	0.050
	D	0.047	0.020	2.320	0.030	0.005	0.089
Monocytes	0	0.211	0.089	2.375	0.026	0.027	0.395
	8	-0.301	0.100	-3.026	0.006	-0.507	-0.095
	D	0.220	0.132	1.665	0.109	-0.053	0.494
Basophils	0	-0.247	0.212	-1.164	0.256	-0.686	0.192
	D	-0.860	0.420	-2.046	0.052	-1.730	0.010
	0	0.586	0.495	1.184	0.249	-0.438	1.611
Albumin	8	-0.016	0.377	-0.044	0.966	-0.796	0.763
	D	-1.469	0.543	-2.706	0.013	-2.593	-0.346
	0	0.201	0.535	0.375	0.711	-0.906	1.307
Globulin	8	0.199	0.297	0.671	0.509	-0.415	0.814
	D	1.221	0.528	2.311	0.030	0.128	2.314

^a By ANOVA, Regression model was found to be significant. The significance values of the different hemogram parameters are highlighted.

^b 0th day before treatment

^c 8th day after treatment

^d day of discharge

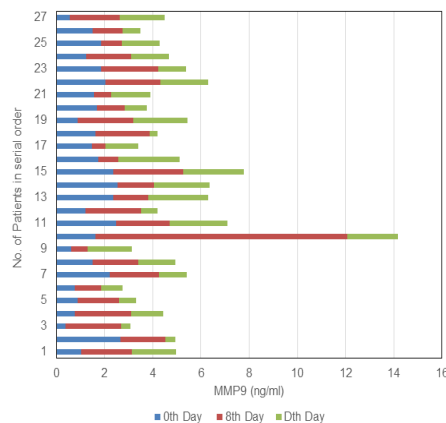


Fig. 3. Matrix Metalloproteinase-9 (MMP9) levels on Day 0, Day 8 and Day D of 27 patients

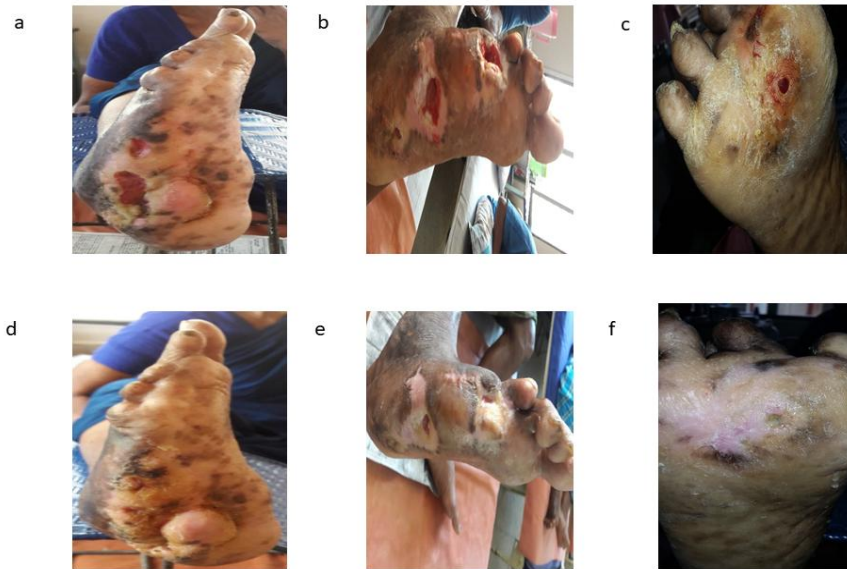


Fig. 4. COL/CS-treated patients feet before (a,b,c) and after (d,e,f) wound dressings

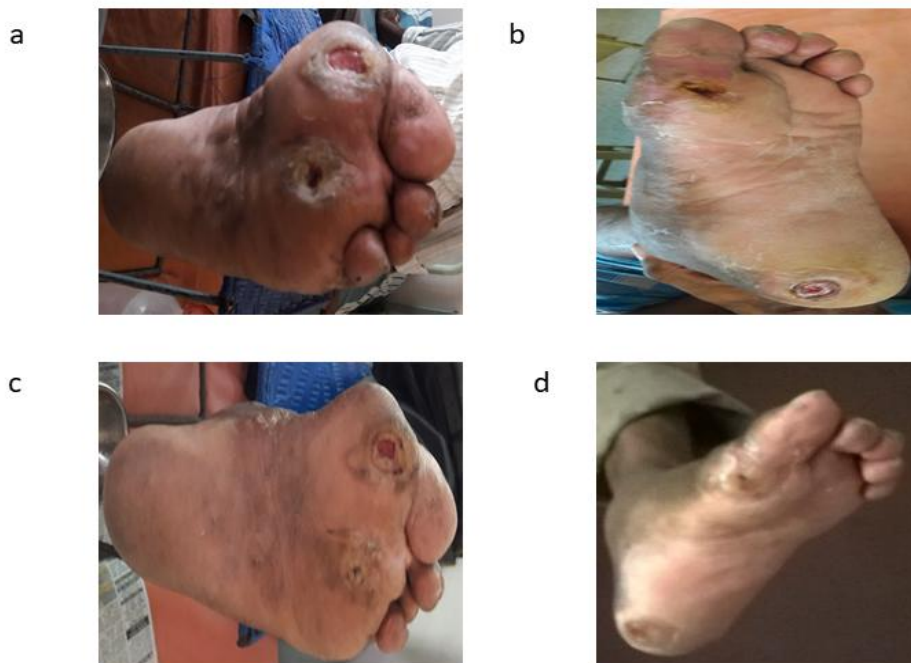


Fig. 5. COL/CS-treated patients feet before (a,b) and after (c,d) wound dressings

4. CONCLUSION

We have studied the effect of a collagen-chitosan powder as wound dressing in the management of chronic wounds in HD patients. The data indicate that wound size was effectively reduced, hemogram analysis showed healing capacity of the biomaterial and MMP9 activity was significantly reduced. Thereby, we have reported

the use of collagen/chitosan biomaterial for healing chronic wounds in HD as an alternative to conventional amniotic membrane dressing.

CONSENT

All authors declare that 'written informed consent' was obtained from the patient (or other approved parties) for publication of this case report and

accompanying images. A copy of the written consent is available for review by the Editorial office/Chief Editor/Editorial Board members of this journal.

ETHICAL APPROVAL

All authors hereby declare that all experiments have been examined and approved by the appropriate ethics committee and have therefore been performed in accordance with the ethical standards laid down in the 1964 Declaration of Helsinki.

ACKNOWLEDGEMENTS

The authors thank the Director, CSIR-Central Leather Research Institute, Chennai, India, for his kind permission to publish this work.

COMPETING INTERESTS

Authors have declared that no competing interests exist.

REFERENCES

1. Mala JGS, Rose C. Role of collagen in Wound healing. In: Chandrasekhar G, editor Collagen: Biosynthesis, Structure and Applications in Biomedicine. CSIR-NISCAIR, New Delhi, India; 2014.
2. Zhang MX, Zhao WY, Fang QQ, Wang XF, Chen CY, Shi BH, Zheng B, Wang SJ, Tan WQ, Wu, LH. Effects of chitosan-collagen dressing on wound healing in vitro and in vivo assays. *Journal of Applied Biomaterials and Functional Materials*. 2021;19:1-10.
3. Rajam AM, Mala JGS, Rose C, Mandal AB. Chitosan-based nanoparticles as growth factor delivery systems for tissue engineering applications. In: Govil JN, editor, *Nanotechnology Vol.11*, Studium Press LLC, USA; 2014.
4. Dong C, Lv Y. Application of collagen scaffold in tissue engineering: Recent advances and new perspectives. *Polymers*. 2016;8:42.
5. Shankar KG, Udhayakumar S, Sowndarya S, Suresh Babu P, Rose C. Isolation, characterization and in vitro evaluation of bovine rumen submucosa films of collagen or chitosan-treated collagen. *Journal of Biomaterials Applications*. 2016;30:780-792.
6. Amaral MB, Viana RB, Viana KB, Diagono CA, Denis AB, Plepis AMG. In vitro and in vivo response of composites based on chitosan, hydroxyapatite and collagen. *Acta Scientiarum Technology*. 2020;42:e41102.
7. Vojtova L, Pavlinakova, V., Muchova, J. Kacvinska, K, Brtnikova J, Knoz M. et al. Healing and angiogenic properties of collagen/chitosan scaffolds enriched with hyperstable FGF2- STAB® protein: in vitro, ex ovo and in vivo comprehensive evaluation. *Biomedicine*. 2021;9(6):590.
8. Feng P, Luo Y, Ke C, Qiu H, Wang W, Zhu Y, Hou R, Xu L, Wu S. Chitosan-based functional materials for skin wound repair: Mechanisms and Applications. *Frontiers in Bioengineering and Biotechnology*. 2021; 9:1-15.
9. Andritoiu CV, Andriescu CE, Danu M, Lungu C, Ivanescu B, Havarneanu C, Popa M. Evaluation of the wound healing potential of some natural polymers on three experimental models. *Pharmaceuticals*. 2021;14:465.
10. Xu R, Luo G, Xia H, He W, Zhao J, Liu B et al. Novel bilayer wound dressing composed of silicone rubber with particular micropores enhanced wound re-epithelialization and contraction. *Biomaterials*. 2015;40:1-11.
11. Zhao X, Wu H, Guo B, Dong R, Qiu Y, Ma PX. Antibacterial, antioxidant, electroactive injectable hydrogel as self-healing wound dressing with hemostasis and adhesiveness for cutaneous wound healing. *Biomaterials*. 2017;122:34-47.
12. Falanga V. Wound healing and its impairment in the diabetic foot. *Lancet* 2005;366:1736-1743.
13. Leng QQ, Li Y, Pang XL, Wang BQ, Wu ZX, Lu Y, Xiong K, Zhao L, Zhou P, Fu SZ. Curcumin nanoparticles incorporated in PVA/collagen composite films promote wound healing. *Drug delivery*. 2020;27(1): 1676-1685.
14. Guo S, DiPietro LA. Factors affecting wound healing. *Journal of Dental Research*. 2010;89(3):219-229.
15. Mohammadi Z, Zak MS, Majdi H, Mostafavi E, Barati M, Lotfimehr H et al. The effect of chrysin-curcumin-loaded nanofibers on the wound healing process in male rats. *Artificial Cells, Nanomedicine and Biotechnology*. 2019;47:1642-1652.
16. Santhanam R, Rameli MAP, Jeffri AA, Ismail WIW. Bovine-based collagen

- dressings in wound care management. *Journal of Pharmaceutical Research International*. 2020;32(33):48-63.
17. Udhayakumar S, Shankar KG, Sowndarya S, Rose C Novel fibrous collagen-based cream accelerates fibroblasts growth for wound healing applications: in vitro and in vivo evaluation. *Biomaterials Science*. 2017;5:1868-1883.
 18. Das A, Abas M, Biswas N, Banerjee P, Ghosh N, Rawat A et al. A modified collagen dressing induces transition of inflammatory to reparative phenotype of wound macrophages. *Scientific Reports*. 2019;9:14293.
 19. Ghomi ER, Khalili S, Khorasani SN, Neisiany RE, Ramakrishna S. Wound dressings: Current Advances and Future directions. *Journal of Applied Polymer Science*. 2019;47738.
 20. Kong Y, Tang X, Zhao Y, Chen X, Yao K, Zhang L et al. Degradable tough chitosan dressing for skin wound recovery. *Nanotechnology Reviews* 2020;9:1576-1585.
 21. Upadya GM, Govindarajan S. Novel treatment for Hard-to-heal chronic plantar ulcers in Hansen's disease. *Journal of Clinical and Diagnostic Research*. 2019; 13(3):WD01-WD03.
 22. Miyashiro D, Cardona C, Valente NYS, Avancini J, Benard G, Trindade MAB. Ulcers in leprosy patients, an unrecognized clinical manifestation: a report of 8 cases. *BMC Infectious diseases*. 2019;19:1013.
 23. Upputuri B, Srikantam A, Mamidi RS. Comorbidities associated with non-healing associated with plantar ulcers in leprosy patients. *PLOS Neglected Tropical Diseases*. 2020;14(6):e0008393.
 24. Kim CL, Kim DE. Self-healing characteristics of collagen coatings with respect to surface abrasion. *Scientific Reports* 2016;6:20563.
 25. Tamer TM, Valachova K, Hassan MA, Omer AM, El-Shafeey M, Eldin MSM et al. Chitosan/ hyaluronan/ edaravone membranes for anti-inflammatory wound dressing: in vitro and in vivo evaluation studies. *Materials Science and Engineering: C: Materials for Biological Applications*. 2018;90:227-235.
 26. Jayakumar R, Prabakaran M, Sudheeshkumar PT, Nair SV, Tamura H. Biomaterials based on chitin an chitosan in wound dressing applications. *Biotechnology Advances*. 2011;29:322-337.
 27. Vijayan A, Nanditha CK, Kumar GSV. ECM-mimicking nanofibrous scaffold enriched with dual growth factor carrying nanoparticles for diabetic wound healing. *Nanoscale Advances*. 2021;3:3085-3092.
 28. Rohani MG, Parks WC. Matrix remodeling by MMPs during wound repair. *Matrix Biology*. 2015;44-46:113-121.
 29. Caley MP, Martins VLC, O'Toole EA. Metalloproteinases and wound healing. *Advances in Wound Care*. 2015;4(4):225-233.
 30. Rayment EA, Upton Z, Shooter GK. Increased matrix metalloproteinase-9 (MMP9) activity observed in chronic wound fluid is related to the clinical severity of the ulcer. *British Journal of Dermatology*. 2008;158:951-961.

© 2021 Babu et al.; This is an Open Access article distributed under the terms of the Creative Commons Attribution License (<http://creativecommons.org/licenses/by/4.0>), which permits unrestricted use, distribution, and reproduction in any medium, provided the original work is properly cited.

Peer-review history:
The peer review history for this paper can be accessed here:
<https://www.sdiarticle4.com/review-history/77035>