



Empyema Thoracis Caused by *Klebsiella Spp* and *Escherichia coli* Co-Infection - An Uncommon Isolation with Atypical Presentation

Maryam Shehu ^{a*}, Hassan Shehu ^b, Judith Bebeyi ^c and Edwin Oseni-Momodu ^b

^a Department of Paediatrics, College of Medicine and Health Sciences, Bingham University/Teaching Hospital, Jos, Plateau State, Nigeria.

^b Department of Surgery, College of Medicine and Health Sciences, Bingham University/Teaching Hospital, Jos, Plateau State, Nigeria.

^c Department of Paediatrics, Bingham University Teaching Hospital, Jos, Plateau State, Nigeria.

Authors' contributions

This work was carried out in collaboration among all authors. Authors HS and MS Conceived the study. Authors JB and EOM wrote the first draft of the manuscript. Authors MS and HS managed the literature searches. All authors read and approved the final manuscript.

Article Information

DOI: 10.9734/AJRID/2022/v9i230264

Open Peer Review History:

This journal follows the Advanced Open Peer Review policy. Identity of the Reviewers, Editor(s) and additional Reviewers, peer review comments, different versions of the manuscript, comments of the editors, etc are available here: <https://www.sdiarticle5.com/review-history/83972>

Case Report

Received 05 December 2021
Accepted 10 February 2022
Published 12 February 2022

ABSTRACT

Empyema thoracis is the collection of pus in the pleural space. A 9-year-old boy presented with a 3-day history of high grade continuous fever, a day history of abdominal pain, distension and fast breathing. Examination findings: acutely ill child, febrile, in respiratory distress. Chest findings: tachypnea, dull percussion note and decreased air entry on the right hemithorax. Chest radiograph: massive fluid collection in the right hemithorax. A pleural tap yielded frank pus that was sent for microscopy, culture and sensitivity (MCS). *Escherichia coli* was cultured which was sensitive to fluoroquinolones. *Klebsiella spp* was also cultured from the blood sample taken for MCS and yielded the same sensitivity. Patient responded well to tube thoracostomy drainage and administration of antibiotics. Empyema thoracis with the isolation of two-gram negative organisms in a previously healthy child is rare.

Keywords: *Empyema thoracis*; *klebsiella specie*; *Escherichia coli*.

*Corresponding author: E-mail: maryamshehu1405@gmail.com;

1. INTRODUCTION

Empyema Thoracis is an important complication of bacterial pneumonia in children. The incidence of an empyema is increasing worldwide [1]. The most common aerobic gram positive organisms that are implicated as a cause of empyema thoracis in over 70% of cultures are *Streptococcus pneumoniae* and *Staphylococcus aureus*. While, for gram negatives organisms, the most common organisms isolated are *Klebsiella*, *Pseudomonas* and *Haemophilus* species [2].

The clinical presentation of patients with empyema thoracis are not different with symptoms of patients presenting with pneumonia. The commonest symptoms include: High grade fever, cough, chest pain and difficulty in breathing [1]. However, Empyema thoracis can present with atypical symptoms like abdominal pain and vomiting [3-4].

The isolation of *Escherichia coli* in a patient with empyema thoracis is not common as it is usually isolated in patients with urinary tract infections, meningitis, cholecystitis, and travelers' diarrhea to mention a few [5]. The isolation of two different aerobic organism in empyema thoracis is rare and is said to occur usually in a patient who came in with community acquired pneumonia and later developed hospital acquired pneumonia due to the use of ventilator [6].

We report an atypical presentation of Empyema thoracis with the isolation of uncommon organisms in a 9-year old boy.

2. CASE REPORT

A 9 year old boy presented with a 3 day history of high grade and continuous fever and a 1 day history of sudden abdominal pain, swelling associated with fast breathing. There was positive history of an episode of generalized tonic convulsion that occurred at the peak of fever, lasting less than 2 minutes, aborted spontaneously with full regain of consciousness. There was also a history of diarrhoea, patronage of food vendors, source of drinking water was tap water. He had no history of vomiting or constipation and no history suggestive of aspiration. Contact and travel history were both non-contributory. He was fully immunized. He is a known seizure disorder patient on carbamazepine. Other systemic review nil of note.

On examination he was fully conscious and alert, acutely ill-looking and in respiratory distress. He was febrile with an axillary temperature of 38.7°C. Respiratory rate was 60cpm and he was saturating at 72% on room air. He had normal percussion notes with transmitted breath sounds. His pulse rate was 160bpm, regular and full volume and apex beat was at the 5th left intercostal space, mid-clavicular line. His heart sounds were S1 and S2 only. Abdominal examination revealed a distended abdomen which was tense with generalized tenderness but more marked at the right upper quadrant. Organs were not palpable on account of distension and percussion note was tympanic. At the time, bowel sounds were not heard. No significant finding upon digital rectal exam.

The patient was provisionally diagnosed as typhoid fever with possible intestinal perforation. He was commenced on intranasal oxygen, antibiotics and intravenous fluids and catheter passed for urine monitoring. Septic work-up, imaging studies and other routine investigations were done.

A Nasogastric Tube was passed to relieve the abdominal distention. Over 400mls of bilious fluid was drained over the course of 4 days. He was started on IV Ceftriaxone, Metronidazole, Gentamicin and maintenance fluids. He was also placed on parenteral acetaminophen to control the fever. Radiograph of the abdomen taken in erect position showed dilated loops of bowel and hepatomegaly.

Patient showed no significant response to treatment up to six (6) days on admission. He was acutely ill looking, spiking temperature between 39-40°C, in respiratory distress, oxygen dependent and restless. Examination of the chest revealed a dull percussion note on the Rt. Hemithorax with decreased breath sounds. Chest radiograph showed homogenous opacity obliterating most of the right lung field. Pleural tapping was done which yielded frank pus. It was sent for gram staining, Ziehl Neelsen staining, microscopy, culture and sensitivity.

Full blood count result on the day of admission, showed WBC – 8700, N-69%, L-22%, M-7%, E-2%, PCV- 31%, Platelets 66,000. Pleural tap biochemistry: Albumin-34g/L, Protein-41g/L. Electrolytes showed moderate hyponatremia but other parameters were within normal range.

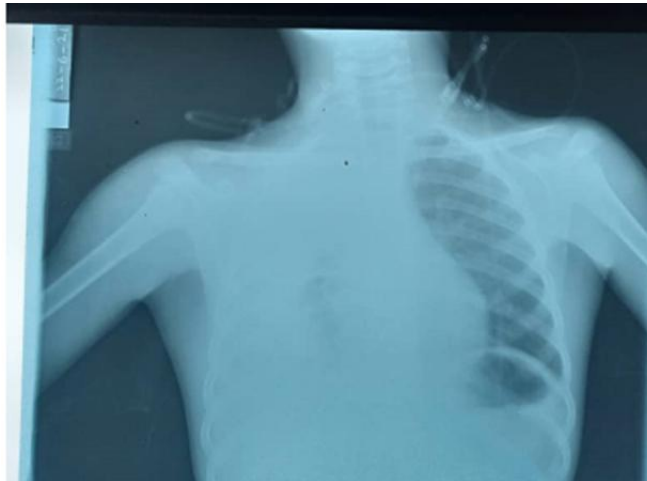

Fig. 1. CXR showing massive right pleural effusion

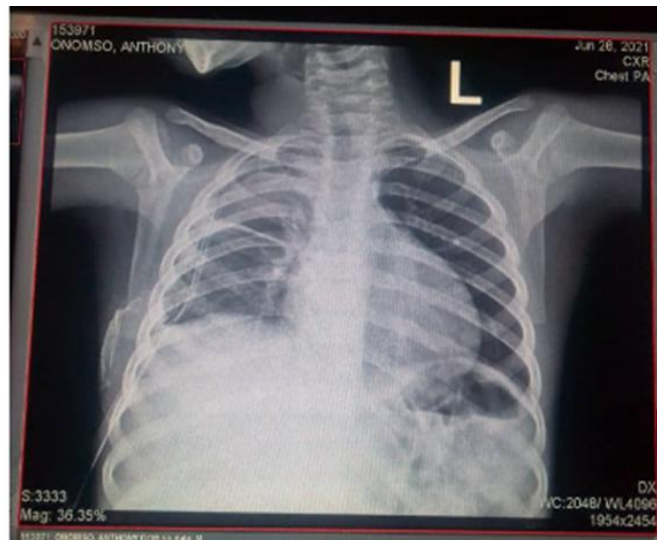


Fig. 2. CXY 8th day post right chest tube thoracostomy

Culture of pleural fluid yielded *E. coli* which was sensitive to only the fluoroquinolones (multi-drug resistant). *Klebsiella* spp was isolated from blood culture and was sensitive to Augmentin, Gentamycin, Cefuroxime and Fluoroquinolones. Patient's retroviral screen was non-reactive. Diagnosis was reviewed to pneumonia complicated by right sided empyema thoracis.

Patient had a chest tube inserted in affected pleural space. On the first day up to 800mls of pus was drained with subsequent days' total of up to 1500mls (over a 5-day period). His medications were reviewed and he was started on Ciprofloxacin. Fever began to take a downward trend with progression of drainage until patient became completely afebrile, he did

well and was discharged home after 14 days on admission.

3. DISCUSSION AND CONCLUSION

There have been reports of children who present with atypical symptoms often times leading to a misdiagnosis of the condition. Our patient presented with symptoms of an acute abdomen and was diagnosed as such. Studies have shown pneumonia to be the most frequent extra-abdominal cause of acute abdominal pain in children [7-8]. Where abdominal symptoms appear more severe than the respiratory symptoms, just like our patient presented, misdiagnosis is more likely [5].

The incidence of empyema complicating pneumonia has been on the rise. Some studies showed that risk factors for developing empyema include use of ibuprofen and acetaminophen prior to hospital admission, our patient received acetaminophen prior to hospital admission [9] Goyal et al observed that girls under the age of 5 years are more susceptible to develop empyema thoracis, and the most common bacteria isolated was *Staph specie* [10]. However, studies done by Elemraid et al observed that age and sex were not significantly associated with Empyema thoracis, but bacteria infection was significantly associated in the development of Empyema thoracis [9].

The patient was diagnosed with right sided pleural effusion. This is similar to what was obtained by studies done by Goyal et al, where more than 50% of the patients had right-sided pleural effusion, although the reason why patients develop right sided pleural effusion more than the left could not be ascertain [10].

Anaemia and malnutrition and previous treatment with antibiotics were risk factors for the development of empyema thoracis in a study, however, our patient was not pale, well-nourished 9 year old boy, with no prior history of antibiotics use before presentation [10].

Klebsiella spp was isolated from the patient's blood stream while *E. coli* was isolated from pleural aspirate. While it is not uncommon to have polymicrobial isolates from a patient, it is a rare finding in patients who have not had any form of instrumentation. Co-infection is common in patients who have developed hospital acquired infection e.g. ventilator-associated pneumonia and catheter-associated UTI. *E.coli* and *Klebsiella spp* are common causative organisms implicated on purulent infections, bacteremia, meningitis and UTI. However, isolation of *E. coli* from the pleural space is uncommon [5]. Isolates are obtained from the same source as against what was observed in the 9 year old boy who had co-infection with organisms isolated from different sites (blood stream and pleural effusion) is what is commonly observed. This could be as a result of passage of the Nasogastric Tube and catheter.

The common mixed organisms usually cultured are *Streptococcus spp* and *Pseudomonas aeruginosa* and the reason is that when patients come with community acquired pneumonia, the commonest organism cultured is usually

Streptococcus spp, however, when they are put to ventilator they can acquire ventilator associated pneumonia usually caused by *Pseudomonas aeruginosa* which is a hospital acquired infection [11].

The *E. coli* cultured in the pleural fluid of the patient was multi-drug resistant, sensitive only to fluoroquinolones. This may be because of the atypical presentation and the possibility of one of the organism being a hospital acquired infection. This is similar to what was obtained by Murugesan et al where the patient had an atypical presentation and the organism cultured was uncommon and was a multi-drug resistant organism [5].

The patient showed significant improvement with insertion of a chest tube and was eventually taken off oxygen, antibiotics were continued and chest tube was eventually removed. However, patient had a longer hospital stay which is as expected in complicated pneumonia where drainage is required [10].

Organisms in the Enterobacteriaceae family are frequently isolated in purulent infections. Co-isolation is seen mostly in hospital-acquired infections where a form of instrumentation is carried out on the patient (catheter associated/ventilator-associated). High index of suspicion is key to early and accurate intervention.

CONSENT

As per international standard, parental written consent has been collected and preserved by the author(s).

ETHICAL APPROVAL

As per international standard or university standard written ethical approval has been collected and preserved by the author(s).

ACKNOWLEDGEMENT

We acknowledge the patient on whom the case report was based.

COMPETING INTERESTS

Authors have declared that no competing interests exist.

REFERENCES

1. Pediatric Empyema thoracis. Available:<https://emedicine.medscape.com/article/1001747-overview>
2. Dwari AK, Jha S, Sarkar S, Misra S, Chakraborty S, Mandal A. A study of bacterial isolates and their sensitivity pattern to antibiotics in empyema thoracis cases in a tertiary care hospital. *J. Evolution Med. Dent. Sci.* 2018;7:4178-81.
3. Pediatric abdominal pain: Consider pneumonia in the differential diagnosis. Available:<https://www.jucm.com/pediatric-abdominal-pain-consider-pneumonia-differential-diagnosis/>
4. Plural Empyema Management in Children. Available:<https://www.olchc.ie/Healthcare-Professionals/Clinical-Guidelines/Pleural-Empyema.pdf>
5. Murugesan M, Arumugam V, Gomatheswari N. Escherichia coli in pleural empyema – An uncommon isolation. *Int.J.Curr. Microbiol. App. Sci.* 2016;5:75-80.
6. Angoulvant F, Levy C, Grimprel E, Varon E, Lorrot M, Biscardi S, Minodier P, Dommergues MA, Hees L, Gillet Y, Craiu I, Zenkhri F, Dubos F, Guen CG, Launay E, Martinot A, Cohen R. Early impact of 13-valent pneumococcal conjugate vaccine on community-acquired pneumonia in children. *Clin Infect Dis.* 2014;58:918-24.
7. Janssen LJ, Voorhoeve PG, van den Wildenberg FJ, van den Brand LR. Acute buikpijn door longontsteking bij kinderen [Acute abdominal pain in children caused by pneumonia]. *Ned Tijdschr Geneeskd.* 2016;160:533-40.
8. Tsalkidis A, Gardikis S, Cassimos D, Kambouri K, Tsalkidou E, Deftereos. Acute abdomen in children due to extra-abdominal causes. *Pediatr Int.* 2008;50:315-8.
9. Elemraid MA, Thomas MF, Blain AP, Rushton SP, Spencer DA, Gennery AR, Clark JE,. North East of England pediatric respiratory infection study group newcastle upon Tyne, UK. Risk Factors For The Development Of Pleural Empyema in Children. *Pediatr pulmonol.* 2015;50:721-6.
10. Goyal V, Kumar A, Gupta M, Sandhu HPS, Dhir S. Empyema thoracis in children: Still a challenge in developing countries. *Afr J Paediatr Surg.* 2014;11:206-10.
11. Detection of the major bacterial pathogens among children suffering from empyema in Ahvaz city, Iran. Available:<https://doi.org/10.1002/jcla.22855>

© 2022 Shehu et al.; This is an Open Access article distributed under the terms of the Creative Commons Attribution License (<http://creativecommons.org/licenses/by/4.0>), which permits unrestricted use, distribution, and reproduction in any medium, provided the original work is properly cited.

Peer-review history:

The peer review history for this paper can be accessed here:
<https://www.sdiarticle5.com/review-history/83972>