



A Rare Case of Meningitis Caused by *Elizabethkingia meningoseptica* in a Baby at the Buea Regional Hospital, South West Region, Cameroon

Kukwah Anthony Tufon ^{a,b*}, Djike Puepi Yolande Fokam ^{a,b},
Enyama Dominique ^c, Akenji Blaise Mboringong ^d,
Belle Ajong Fontem ^e, Linonge Christiana Enjema ^e,
Noukeu Njinkui Diomede ^c, Ekoube Charlotte Eposse ^f,
Andang Paul Mayah ^a, Ganni Wilfried Wele ^b,
Agwe Samuel Mbah ^g
and Tseuko Toghouna Dorine Godelive ^d

^a Buea Regional Hospital, Buea, Southwest, Cameroon.

^b Faculty of Health Science, University of Buea, Buea, Southwest, Cameroon.

^c Faculty of Medicine and Pharmaceutical Sciences, University of Dschang, West Region, Cameroon.

^d National Public Health Laboratory, Yaounde, Centre, Cameroon.

^e Ministry of Public Health, Department for the fight against epidemics and Pandemics, Cameroon.

^f Faculty of Medicine and Pharmaceutical Sciences, University of Douala, Littoral Region, Cameroon.

^g Regional Delegation of Public Health, Southwest, Cameroon.

Authors' contributions

This work was carried out in collaboration among all authors. All authors read and approved the final manuscript.

Article Information

DOI: <https://doi.org/10.9734/ajrid/2024/v15i10384>

Open Peer Review History:

This journal follows the Advanced Open Peer Review policy. Identity of the Reviewers, Editor(s) and additional Reviewers, peer review comments, different versions of the manuscript, comments of the editors, etc are available here:

<https://www.sdiarticle5.com/review-history/123992>

Received: 17/07/2024

Accepted: 19/09/2024

Published: 24/09/2024

Case Report

*Corresponding author: E-mail: drkapt@yahoo.com;

Cite as: Tufon, Kukwah Anthony, Djike Puepi Yolande Fokam, Enyama Dominique, Akenji Blaise Mboringong, Belle Ajong Fontem, Linonge Christiana Enjema, Noukeu Njinkui Diomede, Ekoube Charlotte Eposse, Andang Paul Mayah, Ganni Wilfried Wele, Agwe Samuel Mbah, and Tseuko Toghouna Dorine Godelive. 2024. "A Rare Case of Meningitis Caused by *Elizabethkingia Meningoseptica* in a Baby at the Buea Regional Hospital, South West Region, Cameroon". *Asian Journal of Research in Infectious Diseases* 15 (10):82-89. <https://doi.org/10.9734/ajrid/2024/v15i10384>.

ABSTRACT

Aim: This report was aimed at determining the possible source, risk factors, antimicrobial susceptibility pattern and clinical management of the first recorded case of meningitis in Cameroon caused by *Elizabethkingia meningoseptica*.

Presentation of case: A 10 months old baby previously diagnosed with otitis media was admitted at the Buea regional hospital on the 21st of October 2023 after a referral following unsuccessful treatment. Upon admission, the baby had persistent fever, catarrh (evidence of an upper respiratory tract infection) and abdominal discomfort. Patient developed decreased body movement, altered consciousness and neck stiffness even after being placed on ampicillin and cefotaxime for two days. Based on cerebrospinal fluid analysis, the patient was considered a probable meningitis case and put on ceftriaxone to no avail. CSF culture later revealed the presence of *Elizabethkingia meningoseptica* susceptible to ciprofloxacin and resistant to imipenem, amoxicillin-clavulanic acid, cotrimoxazole, ampicillin and ceftriaxone. Marked improvement was noticed and the patient was discharged following full recovery after treatment with ciprofloxacin for 21 days. Epidemiological investigations and active case search did not provide any evidence of the *Elizabethkingia* being acquired in the hospital.

Discussion and conclusion: The *Elizabethkingia* in this case was most likely community acquired associated with acute otitis media probably linked to a recent upper respiratory tract infection. The isolate was resistant to ceftriaxone and susceptible to ciprofloxacin. In case of meningitis caused by this pathogen, empirical treatment with fluoroquinolones may most likely be an effective option in the absence of antimicrobial susceptibility testing.

Keywords: *Elizabethkingia meningoseptica*; meningitis; otitis media; cerebrospinal fluid.

1. INTRODUCTION

Meningitis is a life-threatening infectious disease that affects millions of people of all ages worldwide [1]. It is considered a major global public health threat that requires prompt diagnosis and treatment [2]. Bacterial meningitis is classified as an epidemic prone disease which warrants immediate notification to the state or local public health officials [3]. The most common aetiologic agents of bacterial meningitis include *Neisseria meningitidis*, *Streptococcus pneumoniae*, *Hemophilus influenzae*, *Listeria monocytogenes* and *Escherichia coli* [4]. A rare aetiologic agent of bacterial meningitis is *Elizabethkingia meningoseptica* [5]. *Elizabethkingia* is a gram negative, non-spore forming rod naturally found in soil, water, the hospital environment (on medical devices, sinks etc) [6] and known to be a common cause of healthcare associated infection [7]. It is an infrequent but noteworthy cause of neonatal meningitis, particularly in premature children [8]. The clinical manifestation of meningitis caused by *Elizabethkingia* is quite similar to that caused by the more common aetiologic agents of meningitis. However, *Elizabethkingia* meningitis regularly leads to more life-threatening complications such as hydrocephalus and brain abscesses [9]. In addition, the microorganism is known for its resistance to many commonly used

antibiotics, making treatment more difficult. As a result, higher case-fatality rates and lasting neurological impairments are more common with meningitis caused by *Elizabethkingia* [8].

Due to the rarity and variability of reported cases across the world, it is quite challenging to determine or come across any study highlighting the prevalence of neonatal meningitis caused by *Elizabethkingia*. To the best of our knowledge, no case of meningitis caused by *Elizabethkingia meningoseptica* has ever been reported in Cameroon. This case report presents a bacterial meningitis caused by *Elizabethkingia meningoseptica* in a baby in Cameroon. This report was aimed at determining the possible source, risk factors, antimicrobial susceptibility pattern and clinical management of meningitis caused by *Elizabethkingia meningoseptica* so as to be able to formulate and implement reliable preventive and management strategies in our setting.

2. PRESENTATION OF CASE

Ten months old male weighing 10kg was brought to and admitted at the Buea Regional Hospital (BRH) on the 21st of October 2023. Background information of the child prior to illness reveals that the HIV negative baby was usually very active although always left indoors, not allowed to play with soil (no ground around the vicinity of

the house), and consumes either tap water or mineral water. From the records seen on the child's vaccination card, all the expanded program on immunization (EPI) vaccines recommended for his age (the most recent one was given on the 26th of September 2023) had been administered.

Prior to hospitalization at the BRH, the baby became unusually less active, developed fever, runny nose and kept crying on the 1st of October 2023 (Table 1). On the 6th of Oct 2023, the mother took the child to a clinic in their neighborhood. A negative rapid diagnostic test (RDT) for malaria and a positive C-reactive protein test were the laboratory findings. The patient was placed on cefixime syrup and artesunate/pyronaridine. The mother was told to go home and continue the treatment for 3 days. Three days later, there was no sign of relief in the child. The mother took the child to another clinic in their neighborhood on the 10th of October 2023. The child presented with persistent fever, abdominal discomfort, restlessness, runny nose, pink conjunctivae and anicteric sclerae. CSF analysis and malaria test (microscopy and RDT) were done and all came back negative. Signs of acute inflammation of the tympanic membrane were noticed and a preliminary diagnosis of Acute otitis media (AOM) established. The child was hospitalized and put on imipenem. After 8 days of hospitalization, the patient still had persistent fever and so was referred to the BRH to see a pediatrician.

The baby was brought to and admitted at the BRH on the 21st of Oct 2023 (9:00 PM). Upon admission, the baby had persistent fever (38.5°C), catarrh and abdominal discomfort. Oxygen saturation ranged between 96-99%. Neurologic examinations revealed hypotonia. Patient was placed on ampicillin 50mg/kg, cefotaxime 50mg/kg and paracetamol. On the 23rd of Oct 2023, patient presented with persistent fever, decreased body movement, altered consciousness, neck stiffness and mild hyperreflexia meeting the case definition of suspected meningitis. Cerebrospinal fluid (CSF) analysis, soluble antigen test for meningitis, blood culture, full blood count (FBC) and cerebral computed tomography (CT) scan were requested. Patient was then put on ceftriaxone, dexamethasone and phenobarbital. The cloudy CSF sample had 260 WBC/ μ l (with 47% being

Neutrophils), a protein level of 1,470 mg/l, and glucose level of 25mg/dl (meeting the case definition of probable meningitis). Blood culture came back negative. Soluble antigen assay (Pastorex meningitis assay BIORAD, California-USA) was negative for *Neisseria meningitidis*, *Streptococcus pneumoniae*, *Hemophilus influenzae* and *Escherichia coli*. FBC revealed 13,300 WBC/ μ l and 46.2% neutrophil. CRP was 12mg/l (Positive). CT scan showed signs of diffused brain atrophy. CSF culture (automated VITEK 2 Advanced Expert system-Biomérieux, USA) revealed the presence of *Elizabethkingia meningoseptica* (meeting the case definition of confirmed meningitis) susceptible to ciprofloxacin and resistant to imipenem, amoxicillin-clavulanic acid, cotrimoxazole, cefixime, ampicillin and ceftriaxone [Based on EUCAST (European Committee of antimicrobial susceptibility testing) 2023 guideline]. On the 17th of November 2023, all the previous antibiotics were discontinued and the patient was put on ciprofloxacin injectable 30mg/kg (Table 1) in two divided doses (for 21 days) and paracetamol injectable 30mg/kg in four divided doses (in case of fever).

Marked improvement was observed in the patient undergoing ciprofloxacin treatment. CSF collected and inoculated on the 4th of December 2023 had no growth. The patient was discharged following full recovery on 8th of December 2023 after 21 days of treatment with ciprofloxacin. The mother admitted 6 months later (June 2024) that the child is doing fine and has not experienced any similar health challenge ever since.

The area which the baby occupied in the pediatric ward of the BRH (the bed, the wall, the tray used by the nurses to place medications, every area the baby touched during his stay as indicated by the mother) was swabbed and well labelled. After inoculation and incubation, the environmental samples grew colonies of varying sizes, texture and colours on blood agar. Although some colonies were pale yellow in colour as expected for *Elizabethkingia* [10], none of them turned out to be gram negative rods.

An active case search was done in the pediatric unit of the BRH during the hospitalization period of the meningitis case and no other child presented with or developed symptoms similar to those found on the *Elizabethkingia* meningitis case.

Table 1. Summary of events and outcomes for the reported *Elizabethkingia meningitis* case

Date	Symptoms	Admission date (duration)	Specimen: tests done	Tests results (Reference values)	Diagnosis	Treatment and outcome (with dates)
1 st Oct 2023	less active, fever, runny nose	Not admitted	None		Unknown	Not stated: No improvement
6 th Oct 2023	fever, runny nose	Taken to a clinic but not admitted	Whole blood: Malaria Serum: CRP	<i>Negative</i> (RV: <i>Negative</i>) 12mg/l (RV: <6mg/l)	Not clear	cefixime and Artesunate: No improvement
10 th Oct 2023	persistent fever, abdominal discomfort, runny nose,	10 th Oct 2023 (8 days)	CSF: WBC CSF: RBC CSF: Gram CSF: Protein CSF: Glucose CSF: Chloride Whole blood: Malaria	05 (RV: ≤05 cells/ul) 00 (RV: ≤05 cells/ul) No bacteria seen 734 (RV: 300-1000mg/l) 41 (RV: 45-72 mg/dl) 121 (RV: 119-130 mmol/l) <i>Negative</i>	Acute otitis media	Imipenem: No improvement
21 st Oct 2023	fever (38.5°C), catarrh and abdominal discomfort	21 st Oct 2023 (48 days)	Whole blood: WBC Serum: CRP Blood culture: CSF: Soluble antigen assay CSF: WBC CSF: RBC CSF: Gram CSF: Protein CSF: Glucose CSF: Chloride CSF Culture	13,300 (RV 5000-19,000 WBC/μl) 12mg/l (RV: <6mg/l) <i>Negative</i> (RV: <i>Negative</i>) <i>Negative</i> (RV: <i>Negative</i>) 260 (RV: ≤05 cells/ul) 00 (RV: ≤05 cells/ul) Gram negative rods: Few 1,470 (RV: 300-1000mg/l) 25 (RV: 45-72 mg/dl) 110 (RV: 119-130 mmol/l) <i>Elizabethkingia meningoseptica</i>	Bacterial meningitis	Ampicillin, cefotaxime (from 21 st Oct to 17 th Nov 2023): No improvement Ceftriaxone (from 24 th Oct to 17 th Nov 2023): No improvement Ciprofloxacin (from 17 th Nov to 8 th of Dec 2023): Recovery

CSF: Cerebrospinal fluid, CRP: C-reactive protein, WBC: White blood cell, RBC: Red blood cell, RV: reference value

Using an incubation period of 2-10 days (average of 4 days) [11], the possible period of exposure was estimated to be 21st to 29th of Sept 2023 (Fig. 1).

3. DISCUSSION

This report presents a rare case of bacterial meningitis caused by *Elizabethkingia meningoseptica* in Cameroon. As compared to most of the other common etiological agents of

bacterial meningitis, *E. meningoseptica* is a non-fastidious microorganism and this implies that it can easily survive in nutrient deficient areas and so can easily be picked up from environmental surfaces even in hospital settings. The mother admitted that the child is usually indoors and not allowed to play with soil or consume non-pipe borne water. No other person (whether from their neighborhood or in the pediatric ward) came down with or complained of symptoms similar to that of the child during their hospitalization. This

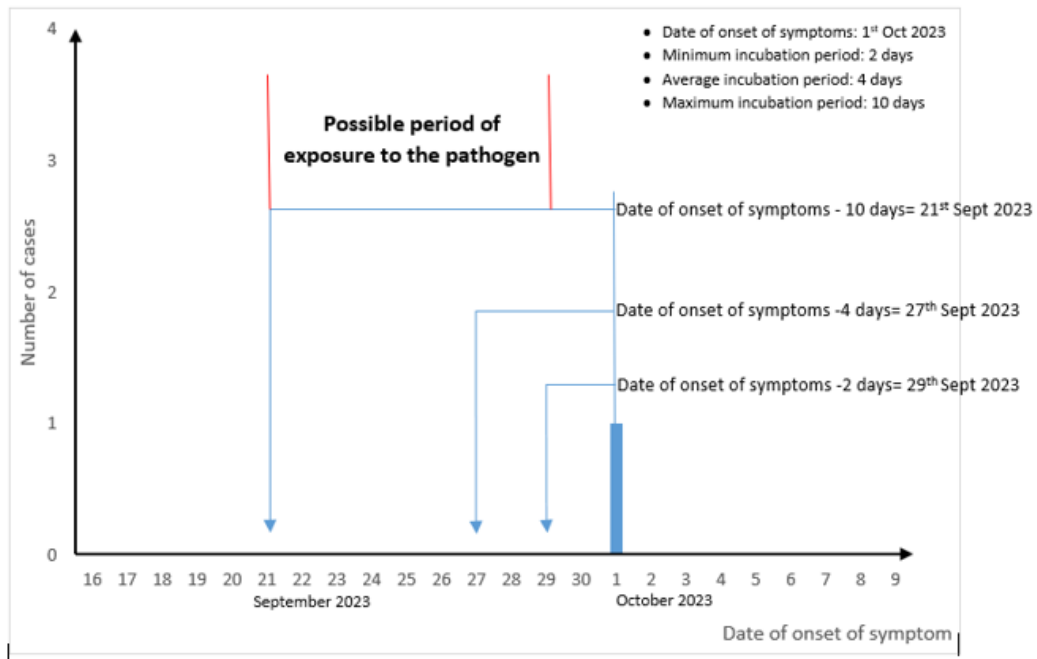


Fig. 1. Estimation of period of exposure for the lone meningitis case caused by *Elizabethkingia meningoseptica* in BRH (2023)

could imply that *Elizabethkingia* is not transmitted from person to person unlike the other bacteria that commonly cause meningitis (*Neisseria meningitidis*, *Streptococcus pneumoniae*, *Hemophilus influenzae*) [11].

The estimated period of exposure was 21st to 29th Sept 2023. During this period the child wasn't hospitalized so this indicates that the infection was most likely not acquired in the hospital. This point is further strengthened by the fact that none of the hospital environmental isolates turned out to be *Elizabethkingia*. Unfortunately, we could only swab and test the hospital environment of BRH and even at that, there is a possibility that the bacteria may have been missed because an enrichment broth was not used unlike in a similar study [7].

The child was clinically diagnosed with acute otitis media (AOM) on the 11th of October and this happens to be a risk factor for bacterial meningitis [12]. There is a possibility that the patient developed bacterial meningitis following the dissemination of the otitis media. Acute otitis media caused by bacteria is usually associated with a current or recent upper respiratory tract infection (this can lead to problems with the eustachian tube) [13]. On the 1st of October 2023, the child developed runny nose and this is usually one of the hall mark symptoms of an

upper respiratory tract infection. There is a possibility that this runny nose was actually an indication of the presence of an upper respiratory tract infection which progressed to otitis media and eventually led to the development of meningitis in this child. At this point it is actually difficult to conclude on the source of the infection since it is just a case and not necessarily an outbreak with many cases that can be linked to a particular source.

It is quite important to understand the etiology of bacterial meningitis caused by *Elizabethkingia* as this could help in prescribing the right antibiotics promptly. Only fever as seen in our study was also found as a common symptom found in similar cases as reported elsewhere (Table 2). We did not come across any recorded case of *Elizabethkingia* meningitis or sepsis in Africa. This bacterium is unexpectedly resistant to colistin but sensitive to vancomycin [7]. Most of the strains are resistant to beta-lactams and sensitive to fluoroquinolones as seen in this case report as well as others (Table 2).

This is an indication that bacterial meningitis caused by *Elizabethkingia meningoseptica* may not be successfully treated empirically following the treatment guideline for bacterial meningitis in Cameroon which mainly involves the use of ceftriaxone.

Table 2. Characteristics and comparison of bacterial meningitis and sepsis caused by *Elizabethkingia meningoseptica* as seen in different studies across the world

Reference	Country	Number of cases	Age	Symptoms/signs	Possible source	Treatment	Outcome
[14]	India	7	neonates	RD*	Hospital acquired	vancomycin, rifampicin, cefoperazone tazobactam	Successful
[5]	USA	1	70 years	Fever, lethargy, RD*, and sepsis.	Hospital acquired	levofloxacin, minocycline, rifampin	Successful
[15]	USA	1	5 years	Fever, neck stiffness, altered mental status	Hospital acquired	ciprofloxacin	Successful
[16]	India	1	1 day	convulsions, sepsis, RD*	Hospital acquired	ciprofloxacin	Successful
[17]	Saudi Arabia	1	New born baby	Decreased consciousness, tachypnea, fever	Hospital acquired	ciprofloxacin, vancomycin, rifampicin	Successful
[18]	India	1	29 years	right-sided paucity and fever	Hospital acquired	tigecycline	Died
[19]		1	78 years	Confusion, weak and shaky	Community acquired	levofloxacin	Successful
[6]	China	24	17 of them >45 years	Fever, cough, altered consciousness	Not determined	cotrimoxazole, levofloxacin, ciprofloxacin,	10 cases died
Our case report	Cameroon	1	10 months	fever, catarrh, abdominal discomfort	Community acquired	ciprofloxacin	Successful

*Respiratory distress

4. CONCLUSION

The *Elizabethkingia* in this case was most likely a community acquired infection associated with acute otitis media probably linked to a recent upper respiratory tract infection. The isolate was resistant to ceftriaxone (first line treatment for bacterial meningitis based on national treatment guideline) and susceptible to ciprofloxacin as also seen in other reports and studies. As such, in case of meningitis caused by this pathogen, empirical treatment with fluoroquinolones like ciprofloxacin may most likely be an effective option in the absence of or while waiting for antimicrobial susceptibility testing.

DISCLAIMER (ARTIFICIAL INTELLIGENCE)

Author(s) hereby declare that No generative AI technologies such as Large Language Models (ChatGPT, COPILOT, etc) and text-to-image generators have been used during writing or editing this manuscript.

ACKNOWLEDGEMENTS

We would love to acknowledge the support from the patient's mother and from all the nurses who took care of the patient during his hospitalization. Special thanks go to the Cameroon Field Epidemiology Training Program (CAFETP) for empowering the team with the appropriate knowledge and skills to investigate this case.

CONSENT

Written informed consent for publication of their clinical details and/or clinical images was obtained from the mother of the child. A copy of the consent form is available for review by the Editor of this journal

ETHICS APPROVAL

An ethical approval (2023/1032-03/UB/SG/IRB/FHS) was obtained from the University of Buea, Faculty of Health Science institutional review board

Competing interests

Authors have declared that no competing interests exist.

REFERENCES

1. Kwambana-Adams B. Global burden of meningitis and implications for strategy. *The Lancet Neurology*. 2023;22:646–8. Available:https://doi.org/10.1016/S1474-4422(23)00244-2.
2. Runde TJ, Anjum F, Wafner JW. Bacterial Meningitis - StatPearls - NCBI Bookshelf 2023.
3. Middleton MR. Bacterial meningitis is a notifiable disease. *BMJ*. 2023;381:1470. Available:https://doi.org/10.1136/bmj.p1470
4. CDC. Bacterial meningitis/CDC 2023. Available:https://www.cdc.gov/meningitis/bacterial.html (Accessed November 26, 2023).
5. Waleed MS, Amba V, Varughese AA, Pathalapati R. *Elizabethkingia meningoseptica* Bacteremia and Meningitis: A Case Report. *Cureus*. 2021; 13:e19275. Available:https://doi.org/10.7759/cureus.19275.
6. Li Y, Liu T, Shi C, Wang B, Li T, Huang Y, et al. Epidemiological, clinical, and laboratory features of patients infected with *Elizabethkingia meningoseptica* at a tertiary hospital in Hefei City, China. *Frontiers in Public Health*. 2022; 10:964046.
7. Ratnamani MS, Rao R. *Elizabethkingia meningoseptica*: Emerging nosocomial pathogen in bedside hemodialysis patients. *Indian J Crit Care Med*. 2013;17:304–7. Available:https://doi.org/10.4103/0972-5229.120323
8. Dziuban EJ, Franks JL, So M, Peacock G, Blaney DD. *Elizabethkingia* in Children: A Comprehensive Review of Symptomatic Cases Reported From 1944 to 2017. *Clinical Infectious Diseases*. 2018;67:144–9. Available:https://doi.org/10.1093/cid/cix1052
9. Hsu M-S, Liao C-H, Huang Y-T, Liu C-Y, Yang C-J, Kao K-L et al. Clinical features, antimicrobial susceptibilities, and outcomes of *Elizabethkingia meningoseptica* (*Chryseobacterium meningosepticum*) bacteremia at a medical center in Taiwan, 1999–2006. *Eur J Clin Microbiol Infect Dis*. 2011;30:1271–8. Available:https://doi.org/10.1007/s10096-011-1223-0.
10. Shinha T, Ahuja R. Bacteremia due to *Elizabethkingia meningoseptica*. *IDCases*. 2015;2:13–5. Available:https://doi.org/10.1016/j.idcr.2015.01.002.
11. WHO. Meningitis; 2023.

- Available:<https://www.who.int/health-topics/ meningitis>
(Accessed November 26, 2023).
12. Richardson MP, Reid A, Williamson TJ, Tarlow MJ, Rudd PT. Acute otitis media and otitis media with effusion in children with bacterial meningitis. *J Laryngol Otol.* 1997;111:913–6.
Available:<https://doi.org/10.1017/s0022215100138964>.
 13. Bakaletz LO. *Otitis Media. Polymicrobial Diseases*, ASM Press; 2002.
 14. Goel S, Jhajra SD, Nangia S, Kumar A, Nanda D. Neonatal Meningitis Secondary to *Elizabethkingia meningoseptica* Infection. *J Glob Infect Dis* 2023;15:23–7.
Available:https://doi.org/10.4103/jgid.jgid_11_22.
 15. Aragón JR, Acosta C, Valencia Y, Manrique V, Arias AF. Device-associated Meningitis due to *Elizabethkingia meningoseptica*: A Therapeutic Challenge. *The Pediatric Infectious Disease Journal.* 2023;42: e360.
Available:<https://doi.org/10.1097/INF.0000000000003987>
 16. Murthy NS, Shivappa SG, Tejashree A, Karthik KMVS, Deepashree R. Neonatal Meningitis with Septicemia by *Elizabethkingia meningoseptica*: A Case Report. *J Lab Physicians* 2022;14: 362–4.
Available:<https://doi.org/10.1055/s-0042-1742635>
 17. Barnawi AI, Kordy FN, Almuwallad OK, Kassarah KA. Early neonatal sepsis and meningitis caused by *Elizabethkingia meningoseptica* in Saudi Arabia. *Saudi Med J.* 2020;41:753–6.
Available:<https://doi.org/10.15537/smj.2020.7.25720>
 18. Nagaraj S, Ravikumar R, Agrawal A, Varun CN, Rao M. Meningitis in a Hospitalized Trauma Patient Due to *Elizabethkingia meningoseptica*: An Emerging Nosocomial Pathogen. *Neurology India.* 2022;70:2260.
Available:<https://doi.org/10.4103/0028-3886.359290>.
 19. Lee JW, Sun B, Hanna M, Rihawi A. A Case of Community-Acquired *Elizabethkingia meningoseptica*. *Cureus.* 2023;15:e45183.
Available:<https://doi.org/10.7759/cureus.45183>

Disclaimer/Publisher's Note: The statements, opinions and data contained in all publications are solely those of the individual author(s) and contributor(s) and not of the publisher and/or the editor(s). This publisher and/or the editor(s) disclaim responsibility for any injury to people or property resulting from any ideas, methods, instructions or products referred to in the content.

© Copyright (2024): Author(s). The licensee is the journal publisher. This is an Open Access article distributed under the terms of the Creative Commons Attribution License (<http://creativecommons.org/licenses/by/4.0>), which permits unrestricted use, distribution, and reproduction in any medium, provided the original work is properly cited.

Peer-review history:

The peer review history for this paper can be accessed here:
<https://www.sdiarticle5.com/review-history/123992>