



# Research Progress on Oral Leukoplakia

**Feng Nianli <sup>a</sup>, Li Ling <sup>b</sup>, Wang Dandan <sup>c</sup> and Fuyong Jiao <sup>d\*</sup>**

<sup>a</sup> Class 7, Stomatology, Class of 2021, Xi'an Medical College, Shaanxi, China.

<sup>b</sup> Xi'an Medical College, Shaanxi, China.

<sup>c</sup> Department of Stomatology, Shaanxi Provincial People's Hospital, Xi'an, China.

<sup>d</sup> Children's Hospital, Shaanxi Provincial People's Hospital, Xi'an, China.

## **Authors' contributions**

*This work was carried out in collaboration among all authors. All authors read and approved the final manuscript.*

## **Article Information**

DOI: <https://doi.org/10.9734/ijtdh/2024/v45i91586>

## **Open Peer Review History:**

This journal follows the Advanced Open Peer Review policy. Identity of the Reviewers, Editor(s) and additional Reviewers, peer review comments, different versions of the manuscript, comments of the editors, etc are available here: <https://www.sdiarticle5.com/review-history/122425>

**Short Communication**

**Received: 22/06/2024**

**Accepted: 27/08/2024**

**Published: 01/09/2024**

## **ABSTRACT**

Oral Leukoplakia (OLK) is a common mottled oral mucosal disease with potential malignant changes, and it is one of the diseases of high concern in dentistry. Through in-depth analysis and review of the existing literature, this summarizes the epidemiological features, clinical characteristics, diagnosis and treatment progress of Oral Leukoplakia, OLK, in order to provide reference for the clinical prevention and treatment of OLK, so as to improve the diagnosis and treatment level.

**Keywords:** Oral leukoplakia; etiology; pathogenesis; clinical manifestations; diagnosis; treatment.

\*Corresponding author: Email: 3105089948@qq.com, 1445983360@qq.com;

**Cite as:** Nianli, Feng, Li Ling, Wang Dandan, and Fuyong Jiao. 2024. "Research Progress on Oral Leukoplakia". *International Journal of TROPICAL DISEASE & Health* 45 (9):26-30. <https://doi.org/10.9734/ijtdh/2024/v45i91586>.

## 1. INTRODUCTION

The definition of oral leukoplakia has been revised and improved many times, and the revision of the definition of oral leukoplakia was restarted at the plenary meeting of Jiamusi in 2006, and was adopted and officially announced in 2011 and has been used up to now. Oral leukoplakia is defined as a predominantly white lesion that occurs on the oral mucosa, which can't be wiped away, or diagnosed with any other definable lesion by clinical and histopathological methods, and belongs to the category of pre-cancerous lesions or potentially malignant disease category, does not include simple hyperkeratosis that can subside after removal of local factors such as smoking or local friction, and does not characterize any other definable damage. [1] In clinical practice, oral leukoplakia can be divided into two general categories: homogeneous and non-homogeneous. The homogeneous type includes plaque-like and crumpled paper-like forms, which present as white patches with a smooth surface. The non-homogeneous type includes granular, wart-shaped and ulcerated, with a rough, hard surface, which may be accompanied by tingling, or slightly rough, with clear borders, and most of them have no self-conscious symptoms.

## 2. ETIOLOGY AND PATHOGENESIS

### 2.1 Etiology

The etiology of oral leukoplakia has not yet been fully clarified, but it is generally believed to be related to a variety of factors. One is local irritating factors. Epidemiological investigation shows that the incidence of leukoplakia is positively related to the length of smoking history and the amount of smoking [2], long-term smoking and alcohol consumption are the main risk factors for oral leukoplakia, and nicotine, nitrosamines and other hazardous substances in tobacco can damage the oral mucosa and cause changes in cellular structure and function; in addition, consuming local physical and chemical stimuli such as excessively hot or acidic food is also an important factor for the onset of leukoplakia [3]; long-term alcohol consumption can also cause stimulation to the oral mucosa and induce the development of oral leukoplakia. Drinking alcohol can also stimulate the oral mucosa and induce white spots. Second, immune factors. The onset of leukoplakia is also related to the abnormal immune function, and the

disturbance of immune system may lead to the decrease of resistance of oral mucosa cells to harmful substances, and the inability to effectively remove the abnormal proliferation of cells, thus increasing the risk of the onset of leukoplakia. Third, microbial infection. Microbial infections such as *Candida albicans* are also one of the important factors in the development of oral leukoplakia, these microorganisms form plaques on the oral mucosa, destroying the mucosal barrier and causing damage to the mucosal cells, which in turn triggers leukoplakia, and leukoplakia accompanied by *Candida albicans* infections-"leukoplakia albicans"-are susceptible to malignant lesions.

### 2.2 Pathogenesis

The pathogenesis of oral leukoplakia is complex, and mainly involves the abnormal proliferation and differentiation of epithelial cells.

## 3. PATHOLOGICAL FEATURES

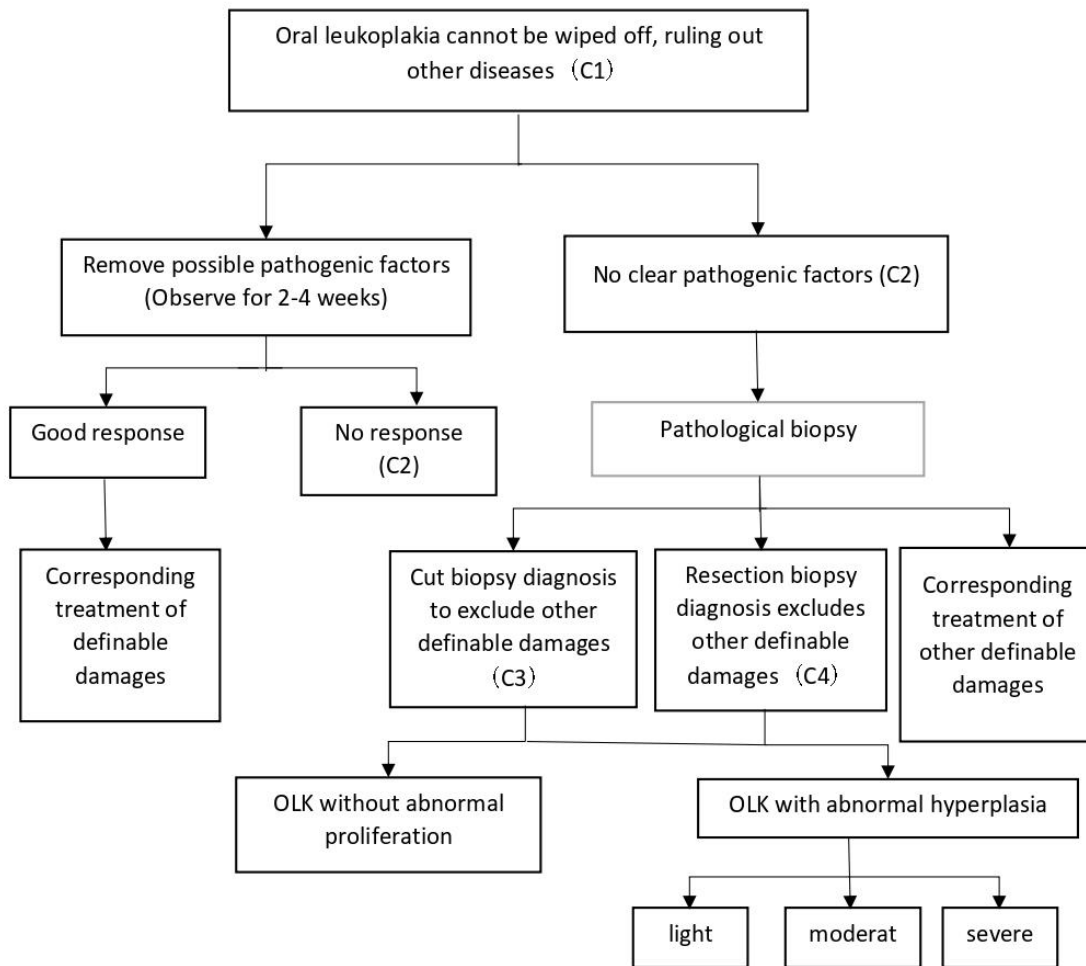
In pathology, leukoplakia is mainly characterized by epithelial hyperplasia, accompanied by hyperkeratosis or hyperinsufficiency of keratinization, elongation and thickening of epithelial pegs, and infiltration of inflammatory cells in the lamina propria and the submucosa. Simple hyperplasia of the epithelium is a benign lesion, while abnormal epithelial hyperplasia refers to an overall disorder of the epithelium, with an increase in epithelial cell anisotropy and a loss of the normal process of cell maturation and differentiation. This change signals a greater tendency for malignant changes in white spots. According to the diagnostic criteria published by WHO in 2017, the determination of the severity of abnormal epithelial hyperplasia depends on the extent of the epithelial layers involved in the 16 features.

## 4. CLINICAL MANIFESTATIONS

Oral leukoplakia is prevalent in middle-aged and elderly people, the prevalence of men is higher than that of women, and the lesion site is mostly in the buccal mucosa and the lip connection, followed by the tongue, jaw, gums and other parts of the tongue, patients generally have no self-awareness of symptoms, and the degree of epithelial keratinization is severe, there can be roughness, wood astringency, loss of taste and other symptoms. Localized hardness, accompanied by ulceration may have spontaneous pain or irritation pain [4].

**Table 1. 16 special WHO criteria for distinguishing the degree of abnormal hyperplasia of oral mucosal epithelium 2017 version**

Structural changes	Cellular changes
Dysregulation Of epithelial layers	Uneven size of cell nucleus
Loss of basal cell polarity	Nuclear polymorphism
Epithelial spikes are droplet shaped	Uneven cell size
Increased mitotic figures	Cellular polymorphism
Mitosis appears on the superficial epithelium	Increase in nuclear cytoplasmic ratio
Keratinization disorder	Abnormal mitosis
Corneal bead appears in the epithelial spike process	Increased and enlarged nucleoli
Decreased cell adhesion	Nuclear chromosome



**Chart 1. Sample procedure**

Note: OLK diagnostic certainty (certainty, c) is divided into 4 levels, C1 is provisional clinical diagnosis, based on the evidence of the initial clinical examination, excluding other definable diseases or damage; C2 is certain clinical diagnosis, no improvement of damage after removing the possible causative factors for 2-4 weeks; C3 is the diagnosis of cut pathologic tissue confirmation, on the C2 based on the combination of excision histopathological examination did not find other definable lesions, showing the damage characteristics of OLK; C4 for excision histopathological confirmation of the diagnosis, oral and maxillofacial surgery excision of all clinically visible damage and the diagnosis made by histopathological examination

## 5. DIAGNOSTIC METHODS

### 5.1 Method

One is clinical examination. Clinical examination is the basis for diagnosing oral leukoplakia, and by observing the white patches on the oral mucosa, combined with the patient's history and clinical manifestations, it can be initially judged whether it is oral leukoplakia. Second, auxiliary examination. In order to further confirm the diagnosis of oral leukoplakia and assess the risk of malignancy, a series of auxiliary examinations are required. These include autofluorescence examination, exfoliative cell examination, toluidine blue staining method, pathologic examination and so on. Among them, pathologic examination is the gold standard for determining oral leukoplakia and its malignancy.

At present, the diagnosis of OLK still needs to refer to the guidelines for the diagnosis and treatment of oral leukoplakia issued by the Oral Mucosal Disease Specialized Committee of the Chinese Stomatological Association in 2011. The procedure chart is as follows in Chart 1.

### 5.2 Differential Diagnosis

Oral Lichen Planus (OLP) is a pre-cancerous state, which is more prevalent in middle-aged women, and it often manifests as a symmetrically distributed. It often shows symmetrically distributed white pearlescent reticular streaks, which are not erasable and may have erosion and ulceration on the surface. Secondly, white keratosis is a benign lesion, which mainly occurs in the areas that have been subjected to long-term mechanical or chemical stimulation. The boundary is unclear, the surface is smooth, and there are no self-conscious symptoms.

## 6. THERAPEUTIC PROGRESS

### 6.1 Physical Therapy

One is Photodynamic Therapy (PTD); PTD removes diseased tissues through the selective aggregation of photosensitizers in the diseased tissues, and the use of laser irradiation triggers a photochemical reaction. PTD has the advantages of small adverse reactions and high cure rate, but the efficacy of the However, the differences in therapeutic efficacy and the development of therapeutic specifications still need to be further researched. The second is laser therapy;

especially CO<sub>2</sub> laser therapy, which has become a recognized treatment for oral leukoplakia due to its good hemostatic effect, clear field and low recurrence rate. [5]

### 6.2 Drug Treatment

**local drugs are as follows:** retinoic acid: has the metabolic effects of promoting epithelial cell proliferation, differentiation, keratolysis, etc., commonly used in the treatment of OLK. Rafael Poveda-Roda et al [7] used 0.1% concentration of isotretinoin to apply locally to the surface of the leukoplakia lesions twice a day, treating 5 cases of OLK patients with a high effective rate. Cao Jun et al. used a paste made of retinoic acid and dexamethasone to apply locally to the leukoplakia, with a treatment efficiency of 95%.

**Bleomycin:** can selectively inhibit squamous carcinoma, can selectively inhibit squamous carcinoma. Epstein JB et al [3] treated 19 cases of OLK with abnormal epithelial hyperplasia with 1% bleomycin, 94% of the patients' condition improved, 75% of the patients' follow-up biopsy saw the abnormal hyperplasia subside.

**Propolis:** local treatment of oral leukoplakia efficacy, can be antibacterial and anti-inflammatory, analgesic, activate blood stasis, soften the keratinized tissue, promote local tissue regeneration. [3]

**Fluorouracil:** to anti-metabolite and play a role, by blocking the deoxyribose uridylic acid by intracellular thymidylate synthetase into thymidylate, interfering with DNA synthesis, there is a report of oral leukoplakia with 5% fluorouracil ointment, the lesion regression rate is high. [3]

### 6.3 Systemic and Combined Traditional Chinese and Western Medicine Treatment

One is systemic treatment; fenviamine-synthesized retinoid derivatives with significant anti-value-added activity. Lippman SM et al. used fenviamine to treat 35 cases of OLK patients who had been previously ineffective or relapsed with retinoic acid, with remarkable efficacy. [3] The second is the combination of Chinese and Western medicine; significant progress has also been made in recent years. Dong Wenjie et al. reported the clinical observation of 60 cases of

oral leukoplakia treated with combination of Chinese and Western medicine, and the efficacy was better than that of simple Western medicine treatment. [7]

#### 6.4 Surgical Treatment

Kuribayashi Y et al [6] reviewed 52 patients with surgical excision of leukoplakia from 2004-2009, and the recurrence rate was 15.4%.

### 7. CONCLUSION

Oral leukoplakia (OLK) as a kind of oral mucosal disease with malignant potential, is of great significance for research and prevention. At present, although there are many treatment methods for OLK, a unified treatment standard has not yet been formed. In the future, with in-depth research on the etiology and pathogenesis of OLK and the emergence of novel treatment methods, the diagnosis and treatment level of OLK will continue to improve.

#### DISCLAIMER (ARTIFICIAL INTELLIGENCE)

Author(s) hereby declare that NO generative AI technologies such as Large Language Models (ChatGPT, COPILOT, etc) and text-to-image generators have been used during writing or editing of manuscripts.

#### CONSENT AND ETHICAL APPROVAL

It is not applicable.

#### COMPETING INTERESTS

Authors have declared that no competing interests exist.

**Disclaimer/Publisher's Note:** The statements, opinions and data contained in all publications are solely those of the individual author(s) and contributor(s) and not of the publisher and/or the editor(s). This publisher and/or the editor(s) disclaim responsibility for any injury to people or property resulting from any ideas, methods, instructions or products referred to in the content.

© Copyright (2024): Author(s). The licensee is the journal publisher. This is an Open Access article distributed under the terms of the Creative Commons Attribution License (<http://creativecommons.org/licenses/by/4.0>), which permits unrestricted use, distribution, and reproduction in any medium, provided the original work is properly cited.

### REFERENCES

1. Specialized committee on oral mucosal diseases of the Chinese Stomatological Association. Definition and grading criteria of oral leukoplakia (for trial implementation) [J]. Chinese Journal of Stomatology. 2011;46(10):57958055555555. DOI:10.3760/cma.j.issn.1002-0098.2011.10.002
2. Li Hui Beng. Paper cigarette smoking and oral mucosal leukoplakia. Chinese Journal of Internal Medicine. 1981;20(10):610-610.
3. Chen Lixia. Research progress of oral leukoplakia [J]. Contemporary Medicine. 2011;17(19):18-19.
4. Liu Xiaohua, Li Tiejun. Research progress of oral mucosal leukoplakia and its malignancy related factors [J]. Department of Special Care, Jinan Stomatological Hospital, Jinan, China; 2015.
5. Wang Rong, Huang Rong, Zhan Chaojun, Wang Peilin, Chen Ruiyang, Liu Chenlu. Progress of research on the treatment of oral leukoplakia [J]. Oral Medicine Research. 2022;06:1-6.
6. Song Yang, Shi Linjun, Zeng et al. Research progress in the treatment of oral leukoplakia [J]. Journal of Clinical Stomatology. 2013;29(4):227-230.
7. Dong WJ, Wang YK, Zhang SY. Combination of Chinese and Western medicine in the treatment of oral leukoplakia in 60 cases [J]. China Traditional Chinese Medicine Modern Distance Education. 2012;02:150-151.

Peer-review history:  
The peer review history for this paper can be accessed here:  
<https://www.sdiarticle5.com/review-history/122425>