



Pulmonary Embolism Complicating Infective Endocarditis: A Pediatric Case Report

Imane Mezdaoui ^{a*}, Fadoua Benbrahim ^a, Naima Elhafidi ^a,
Chafiq Mahraoui ^a and Soumia Benchekroun ^a

^a Department of Pediatric Pneumo-Allergology and Pediatric Infectiology, Rabat Children's Hospital, Ibn Sina University Hospital Center, Morocco.

Authors' contributions

This work was carried out in collaboration among all authors. All authors read and approved the final manuscript.

Article Information

DOI: 10.9734/AJPR/2023/v13i2255

Open Peer Review History:

This journal follows the Advanced Open Peer Review policy. Identity of the Reviewers, Editor(s) and additional Reviewers, peer review comments, different versions of the manuscript, comments of the editors, etc are available here: <https://www.sdiarticle5.com/review-history/100821>

Case Study

Received: 05/04/2023

Accepted: 07/06/2023

Published: 09/07/2023

ABSTRACT

Aims: The study was to highlight pulmonary embolism that is considered a serious and potentially deadly disease. Its incidence in children is probably underestimated and cases reported in the literature, particularly in pediatrics, are rare.

Presentation of Case: we report the case of an 11-year-old male child diagnosed with pulmonary embolism complicating infective endocarditis. A thoracic CT angiography confirmed a distal pulmonary embolus, aneurysms of the lobar and segmental branches of the pulmonary artery and nodules and excavated pulmonary masses in favor of septic emboli. The evolution was unfavorable despite anticoagulant treatment and adequate antibiotherapy.

Discussion: an overview of septic embolism associated with infective endocarditis will be the main topic focusing on key diagnostic and therapeutic choices. An early pulmonary CT angiography in case of any thoracic symptoms that do not evolve favorably in a child is highly recommended.

Conclusion: The identification of other pediatric cases will be useful in order to establish diagnostic and therapeutic guidelines specific to the pediatric population.

*Corresponding author: Email: imane.mezdaoui@gmail.com;

Keywords: Pediatrics; pulmonary embolism; infective endocarditis; child and youth health; early diagnosis; therapy.

1. INTRODUCTION

Pulmonary embolism PE is a rare disease in children [1], but it is associated with a significant mortality estimated at 10% [2]. The clinical presentation is not specific, evoking most often pneumonia, a source of delay in diagnosis that is sometimes only made at autopsy [3]. The septic PEs may have as an initial site bacterial endocarditis of the right heart, septic thrombophlebitis, osteomyelitis, or soft tissue infection [1]. We report the case of a PE complicating an infective endocarditis in an 11-year-old child.

2. PRESENTATION OF CASE

An 11-year-old male child with no known medical history presented to the emergency department with fever and a cough evolving for 15 days. Upon admission, he was alert, his blood pressure was 115/65 mmHg, heart rate 80 bpm, body temperature 39.3°C, respiratory rate 15 breaths per min, peripheral capillary oxygen saturation at 98% and a hepatomegaly of 15cm was revealed in abdominal exam. Initial laboratory parameters found white blood cells (WBC) $20.1 \times 10^3/\mu\text{l}$, lymphocyte count $2.4 \times 10^3/\mu\text{l}$, haemoglobin 10.1 g/dl, platelets $247 \times 10^3/\mu\text{l}$, CRP at 226 mg/l, procalcitonin 4.6 ng/ml. Other laboratory tests including HIV, EBV, viral hepatitis B and C and Parvovirus B19 serologies, cytobacteriological examination of sputum, multiplex PCR respiratory panel, MTB GeneXpert came back negative. A chest computed tomography (CT) showed bilateral and diffuse pulmonary nodules and micronodules, with individualization of several bilateral cavitory images. The patient was

initially put on antibiotics: Cefalotin 150mg/kg/day and Gentamicin 3mg/kg/day. An abdominal CT scan confirmed the hepatomegaly of 16cm.

On the 30th day following admission, he presented a heart murmur and face and leg edema as well as dyspnea with SpO₂: 85%. Infective endocarditis was suspected and a transthoracic echocardiography was performed, it showed large vegetations of the tricuspid valve, with hypokinetic cardiomyopathy and minimal pericardial effusion. Three sets of blood cultures were obtained from the patient and revealed coagulase negative staphylococcus in all three of them. Antibiotic therapy based on Vancomycin 40mg/kg/day, Amikacin 15mg/kg/day + Imipenem/ cilastatin 45mg/kg/day + Metronidazole 30mg/kg/day was started. In addition, curative dose of low molecular weight heparin, Furosemide, Captopril and Digoxin were added to his treatment as well as oxygen therapy with nasal cannula. Control transthoracic echocardiography showed a disappearance of pericardial effusion, decrease in vegetations, improvement in left ventricular ejection fraction.

Given the persistence of clinical signs and the onset of chest pain, a PE was suspected. A thoracic CT angiography confirmed a distal PE, aneurysms of the lobar and segmental branches of the pulmonary artery and excavated pulmonary masses in favor of septic emboli (Fig. 1). On the 47th day following admission, the patient was transferred to the intensive care unit due to respiratory failure. He died on the next day from cardiac and respiratory arrest.

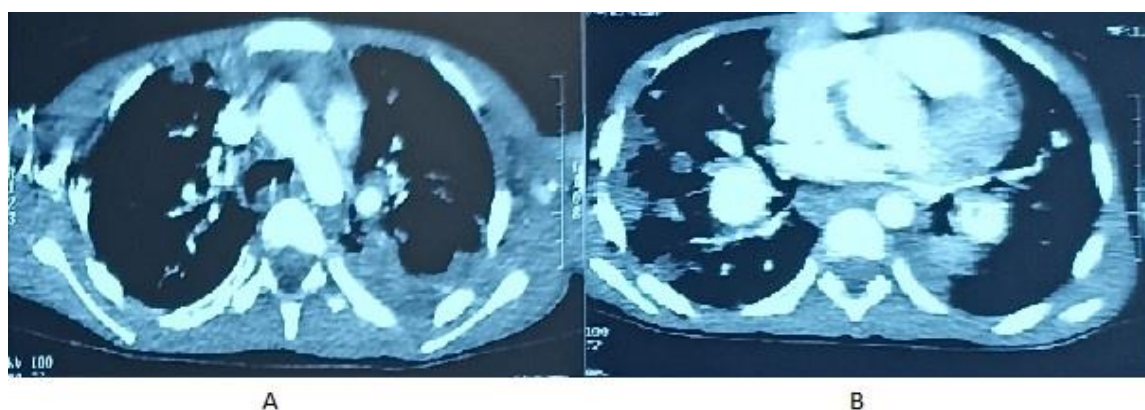


Fig. 1 (A and B). Thoracic CT angiography, axial section: distal pulmonary embolism, aneurysms of the lobar and segmental branches of the pulmonary artery

3. DISCUSSION

Infective endocarditis is relatively rare in children [3]. Several risk factors have been identified: prematurity, the presence of a central venous catheter, cardiac surgery [3,4] and acute articular rheumatism. Children with congenital heart disease are prone to infective endocarditis, the risk depends on the type of heart disease, ventricular septal defect having the highest risk [5]. No risk factor was identified with our patient. Streptococcus and staphylococcus are the most frequently encountered germs [4,5], while enterococci are only seen in 5 to 15% of cases and are characterized by their subacute character [5] and a rate of lower mortality. The evolution of endocarditis in our case report was insidious and subacute. Three sets of blood cultures were obtained from the patient and revealed coagulase negative staphylococcus in all three of them.

Pulmonary embolisms complicate 14% of infective endocarditis [5]. In approximately 60% of cases, the right heart is the one concerned with endocarditis and the lesions are always multiple [5-7]. The transthoracic echocardiography in our case showed large vegetations of the tricuspid valve, with hypokinetic cardiomyopathy and minimal pericardial effusion.

PE is rare in children; its incidence being approximately estimated from 0.14 to 0.9/100,000 in the general population and from 8.6 to 57/100,000 in hospitalized children. We can note a first peak in infants (0-1 year) then a second peak in adolescence [3]. Our patient was 11 years old at the time of diagnosis.

The clinical picture depends on the rate of development of the embolism, the degree of vascular obstruction, the release of vasoactive amines and the previous state of cardiopulmonary functions [1,3]. Classically, it presents with dyspnea, fits of dry cough, chest pain and hemoptysis with nonspecific infiltrates on chest radiography [1,5,8], unfortunately, these signs are only observed in massive PE, in other cases, the presence of vague respiratory symptoms may mimic other respiratory illnesses. In our observation, only dyspnea and chest pain were present.

There is no official algorithm for the diagnosis of PE in children. All guidelines are based on adult

literature and should be used with precaution in pediatrics.

The Chest X-ray is often normal [3]. It could show atelectasis, pleural effusion, elevation of a diaphragmatic dome, an image of pulmonary infarction, an image of amputation of a pulmonary artery or pulmonary hyperclarity, a cardiomegaly [3]. It makes it possible to exclude an infectious pneumopathy, a pneumothorax, acute pulmonary edema [3]. The thoracic spiral CT angiogram (CT angiography) is the reference exam for the diagnosis. There is no equivalent data in pediatrics, but its position of choice in pediatric PE comes from its availability, its speed of execution, its high spatial resolution and its image capacity in 2D/3D [8,9]. The PE is visualized in the form of a central lacuna or intraluminal margin totally or partially occupying the section of the vessel [3]. In our case, it confirmed a distal PE, aneurysms of the lobar and segmental branches of the pulmonary artery and nodules and excavated pulmonary masses in favor of septic emboli. Its normality however does not exclude the diagnosis of PE [8,9]. Magnetic resonance imaging/ magnetic resonance pulmonary angiography MRI/MRPA seems a better option due to the use of safer contrast agents and no ionizing radiation an attractive option for clinicians. However, its effectiveness and reliability are not proven in children population [8]. Lung perfusion and ventilation scintigraphy has historically been a reference examination with a specificity of 100% [8,9]. Its normality excludes the diagnosis of PE [10]. A positive V/P (ventilation/perfusion) scan may be positive in cases of pneumonia, sickle cell disease, arterial stenosis and air/fat/foreign body embolism [8,10]. It is a harmless and sensitive examination, easy to achieve without resorting to the use of contrast agent, important conditions in children [3,8,9]. D-dimer is sensitive but not specific for PE, it is not validated for use in children [8,9].

There is no treatment algorithm for PE in pediatrics so far. The treatment recommendations are extrapolated from adults but must be adapted to pediatric pharmacological and etiological specificities. Anticoagulant therapy remains the most widely used initial treatment in pediatrics in hemodynamically stable patients. Our patient received curative dose of low molecular weight heparin. The duration varies between 3 and 12 months [5,8]. Thrombolytics allow rapid fibrinolysis of thrombi but could cause a hemorrhage. They are

reserved for unstable patients at high risk of PE but should be discontinued in children at risk of bleeding [8,9]. Mechanical thrombolysis is rare in pediatrics and reserved for recidivists despite well-conducted anticoagulant treatment or after surgical embolectomy [9]. Surgical embolectomy is exceptionally performed during PE very serious with shock, in case of contraindication to thrombolytics or failure of thrombolytic therapy [3]. Promising new therapies such as echo-assisted thrombolysis are yet to be studied in pediatrics. In the treatment of septic PE like our case, infective endocarditis should be managed with antibiotics as well. Moreover, the prevention of bacterial endocarditis is a key element.

4. CONCLUSION

Childhood PE is a rare condition, but its incidence is underestimated. A better knowledge of its real incidence and its causes in children is desirable, whereas the current recommendations concerning diagnosis and therapeutic management are derived from those of adults.

CONSENT

All authors declare that 'written informed consent was obtained from the patient's father for publication of this case report and accompanying images.

ETHICAL APPROVAL

As per international standard or university standard written ethical approval has been collected and preserved by the author(s).

COMPETING INTERESTS

Authors have declared that no competing interests exist.

REFERENCES

1. Mansour B, Habib A, Asli N, Geffen Y, Miron D, Elias N. A case of infective endocarditis and pulmonary septic emboli caused by *Lactococcus lactis*. Case Reports in Pediatrics. 2016;2016:1–4.

2. Mornand P, Chalard F, Romain AS, Rohr M, Paluel-Marmont C, Niakaté A, et al. Embolie pulmonaire bilatérale mimant un syndrome thoracique aigu chez un adolescent drépanocytaire. Archives de Pédiatrie. 2017;24(7):625–9.
3. Gueulette E, Somville V, Marchand AS, Bodart E. Pulmonary embolism : about two pediatric observations.
4. Song X yu, Li S, Cao J, Xu K, Huang H, Xu Z jun. Cardiac septic pulmonary embolism: A retrospective analysis of 20 cases in a Chinese population. Medicine. 2016; 95(25):e3846.
5. Wojda TR, Cornejo K, Lin A, Cipriano A, Nanda S, Amortegui JD, et al. Septic Embolism: A Potentially Devastating Complication of Infective Endocarditis. In: Firstenberg MS, editor. Contemporary Challenges in Endocarditis [Internet]. InTech; 2016 [cited 2023 Feb 4]. Available:<http://www.intechopen.com/books/contemporary-challenges-in-endocarditis/septic-embolism-a-potentially-devastating-complication-of-infective-endocarditis>
6. Shimada H, Tanaka M, Takami Y, Teragaki M, Maeda K, Saita H, et al. A case of septic pulmonary embolism caused by *P. aeruginosa* in a hemodialysis patient and review of the literature. Ren Replace Ther. 2020;6(1):13.
7. Träger LH, Knudsen PJT, Leth PM. Right-sided acute infective endocarditis with septic pulmonary embolism: Postmortem computed tomography and forensic autopsy findings. A case report. Forensic Imaging. 2021;26:200469.
8. Zaidi AU, Hutchins KK, Rajpurkar M. Pulmonary Embolism in Children. Front Pediatr. 2017;5:170.
9. Navanandan N, Stein J, Mistry RD. Pulmonary Embolism in Children. Pediatric Emergency Care. 2019;35(2).
10. Agrawal S, Shrivastava Y, Panda PK, Sharawat IK, Bhat NK. Pulmonary Embolism in Children: A Case Series. Indian Journal of Critical Care Medicine. 2020;24(12):1272–5.