



Prevalence of Osteomyelitis in Jaws among the Patients Visiting Private Dental Hospital: An Institutional Study

L. Akshayaa^a and Pratibha Ramani^{b*}

^a Saveetha Dental College and Hospitals, Saveetha Institute of Medical and Technical Sciences
Saveetha University, Chennai - 77, Tamil Nadu, India.

^b Department of Oral pathology, Saveetha Dental College and Hospitals, Saveetha Institute of Medical
and Technical Sciences Saveetha University Chennai - 77, Tamil Nadu, India.

Authors' contributions

This work was carried out in collaboration between both authors. Both authors read and approved the final manuscript.

Article Information

DOI: 10.9734/JPRI/2021/v33i64B35781

Open Peer Review History:

This journal follows the Advanced Open Peer Review policy. Identity of the Reviewers, Editor(s) and additional Reviewers, peer review comments, different versions of the manuscript, comments of the editors, etc are available here:
<https://www.sdiarticle5.com/review-history/81723>

Original Research Article

Received 20 October 2021
Accepted 28 December 2021
Published 30 December 2021

ABSTRACT

Introduction: Osteomyelitis is an inflammatory condition of bone that involves the medullary cavity and periosteum. The prevalence rate of this disease was found predominantly among the males than females with an incidence of 30-39 years. This condition involves one or more facial bones in the head and neck, mainly mandible, frontal bone, cervical spine, maxilla and nasal bones. Various types of osteomyelitis are acute, primary chronic suppurative and secondary chronic and fungal osteomyelitis.

Aim: To assess the prevalence rate of osteomyelitis in jaws among the patients visiting private dental hospitals in Chennai.

Materials and Methods: This present study was carried out in a private dental hospital under a university setting, in Chennai. Sample size for the present study includes the patients who were diagnosed with osteomyelitis from Jun 2019 to Feb 2021 which was collected using the Dental hospital management system. Sample size of the study was found to be n= 5 cases of osteomyelitis in jaws among 5,35,951 patients. The data collected was verified and tabulated in excel and statistically analysed using SPSS software. Chi square test was done to compare the

[≡] Professor and Head;

*Corresponding author: E-mail: pratibaramani@saveetha.com;

groups ($p < 0.05$) which shows the significance and the results were interpreted.

Results : Among the total patients, 40 % of them were males and 60 % of them were females. It was observed that 60 % of the subjects had acute osteomyelitis, 20 % with chronic suppurative and fungus associated osteomyelitis and found to be more prevalent among the individuals who were aged between 41-50 years. Majority of the females, 40% were highly affected with acute osteomyelitis than males, 20% of them were affected. However, p value less than 0.05 is considered as statistically significant, here the chi square test p value = 0.329, as ($p > 0.05$) it is insignificant.

Conclusion: The prevalence of osteomyelitis has recently decreased in developing countries, as attributed to the improvement in the oral and dental care with standard antibiotic treatment. From the results of our study it is evident that out of 5 cases of osteomyelitis in jaws, the majority of patients 60% were diagnosed with acute osteomyelitis. This shows that there is a reliable prevalence of osteomyelitis in jaws among the patients who are visiting private dental hospitals.

Keywords: Osteomyelitis; prevalence; dental hospital; innovative technology; novel method.

1. INTRODUCTION

Osteomyelitis is an inflammatory condition of bone that involves the medullary cavity and periosteum. The prevalence rate of this disease was found to be predominantly among the males than females with an incidence of 30-39 years [1,2]. It is more commonly encountered in areas of poor socioeconomic status as a critical disorder in developing countries. As osteomyelitis condition may involve one or more facial bones in head and neck, mainly mandible, frontal bone, cervical spine, maxilla and nasal bones, but maxilla is less commonly affected than that of mandible due to its high vascular nature [3,4]. In some instances, there may be a lack of awareness of osteomyelitis, its clinical features which often leads to misdiagnosis and delay in the treatment. The etiological factors associated with osteomyelitis include traumatic injuries, fungal infections, radiation, poor oral hygiene, chemical agents etc [5]. Several systemic diseases like diabetes, anemia, malnutrition also influence the progression of osteomyelitis [6,7]. This disorder mainly involves the mandible which is rarely attributed to the bisphosphonates therapy or radiotherapy or from bacterial infection from odontogenic origin. Other disease conditions which predispose to osteomyelitis are malignancy, osteoporosis and Paget's disease [8,9].

Various types of osteomyelitis include acute, primary chronic and secondary chronic suppurative, and fungal osteomyelitis. The acute and secondary chronic suppurative osteomyelitis of the jaws mostly developed from the existing pulpal or periodontal infections, extracted wounds and odontogenic disease [10,11]. Abrupt events of signs and symptoms indicated during

the initial stage of infection may lead to acute osteomyelitis. If this condition passes without the removal of infection, it results in subacute or chronic suppurative osteomyelitis [12]. Few studies have reported that, bacterial species also implicated in spread of osteomyelitis, most common pathogens are staphylococci and streptococcal species. These organisms may also result in contagious spread of disease from the soft tissues to the bones through direct infusion of microbes into the bone leading to osteomyelitis [13].

The typical clinical features seen in osteomyelitis affected individuals are edema, pain and formation of fistula. Radiologically, this condition illustrates a fine radiopaque image with an unclear margin with bony destructions [14,15]. Early diagnosis of osteomyelitis is reliable by tissue biopsy and a surgical approach by an excision or removal of infection with concurrent antibiotics. Several retrospective studies have reported the prevalence rate, risk factors and management of osteomyelitis [16,17]. A clinical study done among 34 adult patients, with chronic suppurative osteomyelitis of the mandible reported that periodontal lesions are found to be the main etiological factor associated with osteomyelitis [18,19]. Thus our present study aims to assess the prevalence rate of osteomyelitis among the patients visiting the private dental hospital in Chennai.

2. MATERIALS AND METHODS

This present study was carried out in a private dental hospital under a university setting, in Chennai. The sample size for the present study includes the patients who were diagnosed with osteomyelitis from Jun 2019 to Feb 2021 which

was collected using the Dental hospital management system. Sample size of the study was found to be n= 5 cases of osteomyelitis in jaws among 5,35,951 patients. The ethical approval was obtained from the institutional ethical committee (ethical approval number : (SDC/SIHEC/2021/DIASDATA/O619-0320). The tabulated data was imported to spss software (statistical package for social studies) version 22.0(IBMcorporation) for statistical analysis. As our study was retrospective, data collection was done by simple random sampling methods within the university to minimise sampling bias. Each osteomyelitis case which was observed in the maxillary and mandible of patients were recorded for our study. The parameters of the study include the patient's demographic details such as name, age, gender, medical history, examination findings and type of osteomyelitis were noted. The diagnosis was confirmed with the help of orthopantomogram, X rays of skull bones and biopsy with histopathological findings. Improper and incomplete data and repeated data, were excluded from the study. The validity of data collected was checked by internal and external reviewers. Then all the data collected was verified and tabulated in excel and statistically analysed using SPSS software. Chi square test was done to compare the groups ($p < 0.05$) which shows the significance and the results were interpreted.

3. RESULTS

In our present study, a total of n= 5 patients who are diagnosed with osteomyelitis in both maxilla and mandible were collected. The age, sex and

site predilection were analysed. The patient's age ranged from 30 to 70 years. We assessed the prevalence and type of osteomyelitis affected in the patients. Among the total patients, 40 % of them were males and 60 % of them were females. It was observed that 60 % of the patients had been diagnosed with acute osteomyelitis, 20% of them diagnosed as chronic suppurative and fungal osteomyelitis [Figure 1]. From the results obtained, we found that 20% of the patients who had fungal osteomyelitis, have a medical history of diabetes. And 20 % of them were diagnosed with chronic suppurative type of osteomyelitis. In our study, maxilla is the most commonly affected site when compared to mandible. The predilection of sites affected in all the 5 patients with osteomyelitis were found to be 40% of the patients were affected in maxillary left posteriors, 20% of those patients were diagnosed in the mandibular posterior regions [Figure 2]. The prevalence of osteomyelitis among different age groups of people visiting private dental hospitals in Chennai. It was observed that osteomyelitis was more prevalent among the patients who are aged between 41-50 years [Figure 3]. The correlation between the gender of the patients and type of osteomyelitis affected them was analysed. Majority of the females, 40% were highly affected with acute osteomyelitis than males, 20% of them were affected. However, p value less than 0.05 is considered as statistically significant, here p value = 0.329, as ($p > 0.05$) hence it shows not significant [Figure 4]. This shows that acute osteomyelitis is more prevalent in patients than other types such as chronic suppurative and fungal osteomyelitis.

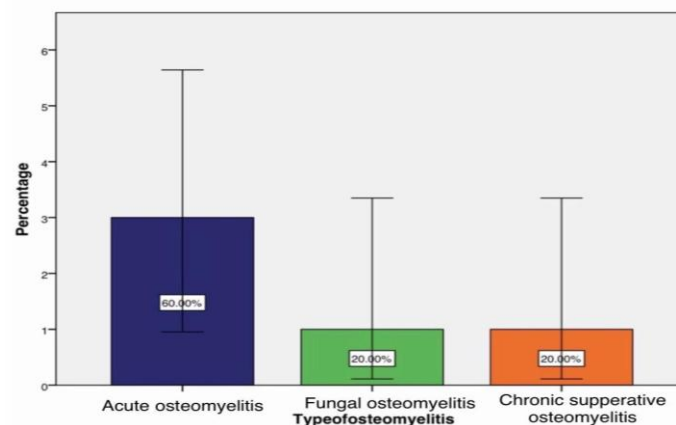


Fig. 1. This bar graph represents the prevalence rate and type of osteomyelitis in patients visiting the dental hospital in Chennai. It shows that 60% of the patients were diagnosed with acute osteomyelitis, 20% of them with chronic suppurative and fungus associated osteomyelitis

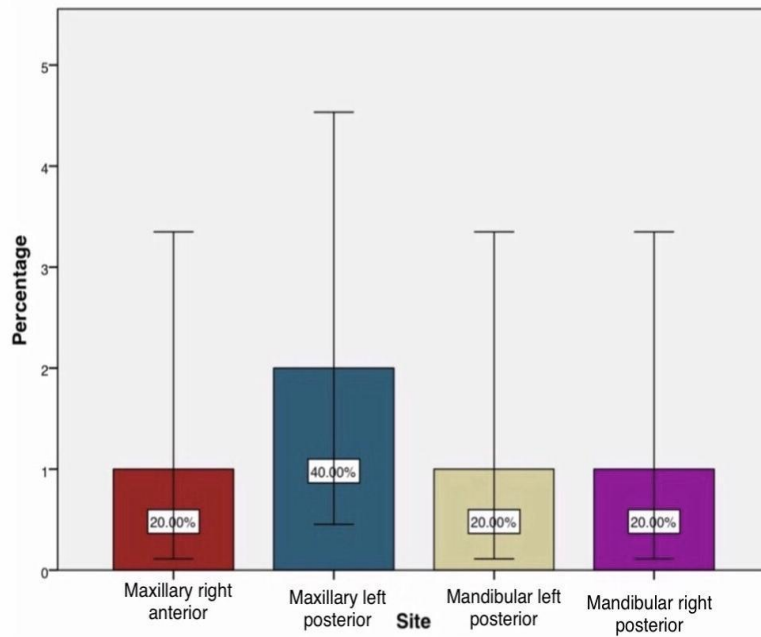


Fig. 2. This bar graph represents the most common site affected in each type of osteomyelitis. It shows that 60 % of the patients have osteomyelitis in maxillary posteriors and 20% of the individuals with mandibular posteriors affected

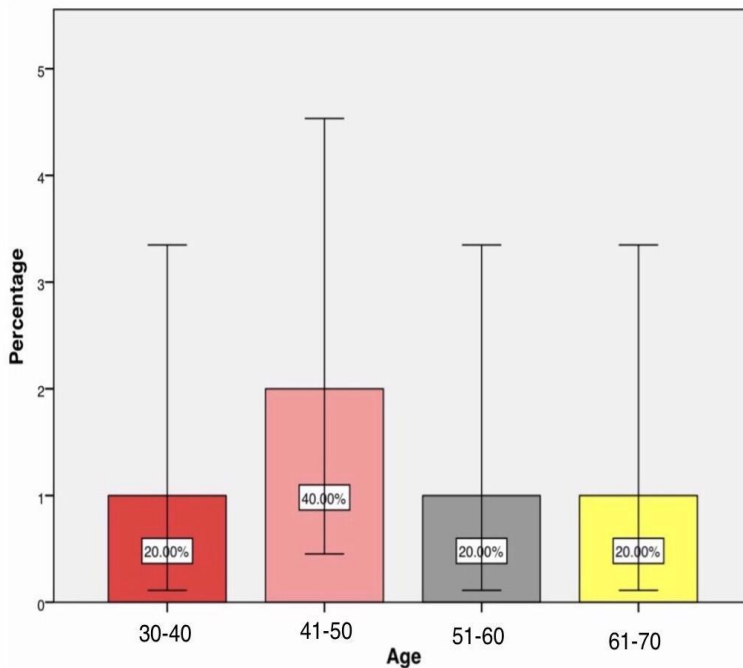


Fig. 3. Bar graph represents the prevalence of osteomyelitis among different age groups of people visiting private dental hospitals in Chennai. Here, the graph shows that osteomyelitis was found to be more prevalent among the individuals who are aged between 41-50 years (40%)

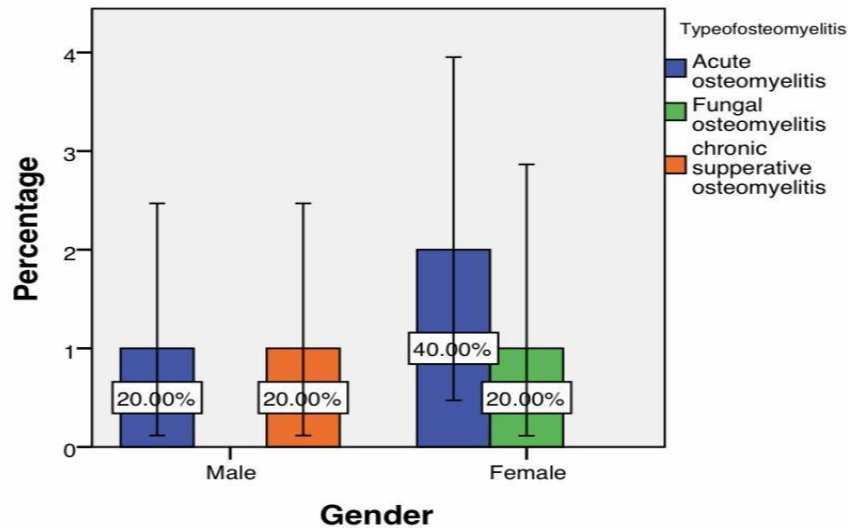


Fig. 4. Bar graph represents the association between the gender of the patients and type of osteomyelitis affected in them. The Chi square test ; p value = 0.329 ; which is $p > 0.05$, hence it shows statistically insignificant. It shows that the majority of females (40%) are highly affected with acute osteomyelitis when compared to males (20%)

4. DISCUSSION

An epidemiological study done by Kremers et al, reported that osteomyelitis in the patients diagnosed in a tertiary centre shows an incidence of infection in the patients aged 36- 45 years. It also concluded that the maxilla was more commonly affected than the mandible in the patient suffering with osteomyelitis [19]. From the results obtained in our study, it has also been found that osteomyelitis is more prevalent among the age group 41-50 years. Another study done by Koerbusch et al detailed that females are more affected with osteomyelitis with a younger age group than males. So, consequently the younger age group, less than 40 years is more predisposed to osteomyelitis when exposed to the same risk factors. Likewise, in our study we observed that osteomyelitis is more predominantly in females when it was compared to male patients [20].

A similar study done by Prasad et al, reported the prevalence rate of osteomyelitis in head and neck. For which, 88 patients with osteomyelitis, nine of them were diagnosed as acute osteomyelitis [11%], 75 were diagnosed as chronic osteomyelitis [89%] [21,22]. So the clinical conditions reported with osteomyelitis seem to present with abrupt symptoms such as pain, fever, swelling over the cheek, reduced joint movement with early radiological changes. As contrast to our findings, a similar study

reported that the mandible was the most common bone affected in radiation induced ORN osteomyelitis [23,24]. Another study has found that in both acute and chronic forms of osteomyelitis, posterior mandible and maxillary regions are often affected (45). In our study it has been illustrated that 20% of female patients are diagnosed with fungal osteomyelitis in the maxillary anterior region. Likewise similar findings with a case report study done on mucormycosis osteomyelitis involving the maxilla. It was found that the majority of the patients are diagnosed with the fungal osteomyelitis involving the maxillary sinusitis and it is associated with diabetes [26].

A clinical study done related to the osteomyelitis of the mandible, reported that trauma is the most common cause for osteomyelitis [27,28]. In our study, we observed that odontogenic infections, tooth extractions were found to be the predisposing factor for chronic osteomyelitis which was diagnosed and treated with antibiotics. A previous study done by Wurman LH, et al, found that osteomyelitis of the mandible caused secondary to dental extraction, were treated with surgical method and long term antibiotics [29]. An earlier study reported that contagious infections such as maxillary sinusitis, odontogenic diseases indicated to be the reliable factor associated with the maxillary osteomyelitis [30]. The clinical features of osteomyelitis include swelling of jaws, edema with throbbing pain,

gingival enlargement and distension of periosteum. The management of osteomyelitis of the jaws includes cessation of the cause, incision and drainage, sequestrectomy, resection of the jaw, antibiotics and hyperbaric oxygen therapy [31]. Despite the fact that there is a rare occurrence of osteomyelitis, its differential diagnosis includes tumours, which can be radiologically comparative. Furthermore it impersonates the scintigraphic findings just as the other disorders of bone such as fibrodysplasia, paget's disease and osteosarcoma [32].

Our present study had certain limitations, as it is a retrospective study we found only less number of osteomyelitis cases in jaws. We excluded a certain number of cases which had improper diagnosis and did not mention the correct type of osteomyelitis in patients. Thus the future extent of our study relies on better knowledge of osteomyelitis, its features and management. However, our study should have a long term follow up with the patients for better understanding of this disease condition in terms of its prevalence rate, radiological and histological findings of osteomyelitis.

5. CONCLUSION

The prevalence of osteomyelitis has recently been decreased in developing countries, as attributed to the improvement in the oral and dental care and with standard antibiotic treatment. From the obtained results, it is evident that out of 5 cases of osteomyelitis in jaws, the majority of patients 60% were diagnosed with acute osteomyelitis. This shows that there is a reliable prevalence of osteomyelitis in jaws among the patients who are visiting private dental hospitals. So an effective treatments like systemic antimicrobials, surgical approach with incision and drainage, sequestrectomy can be executed in the field of dentistry to prevent the occurrence of osteomyelitis.

CONSENT

As per international standard or university standard, patients' written consent has been collected and preserved by the author(s).

ETHICAL APPROVAL

The ethical approval was obtained from the institutional ethical committee (ethical approval number: (SDC/SIHEC/2021/DIASDATA/O619-0320).

ACKNOWLEDGEMENT

The authors are thankful to the Department of Oral and Maxillofacial Pathology, Saveetha Dental College, Saveetha Institute of Medical and Technical science, Saveetha University for providing a platform in expressing their knowledge.

COMPETING INTERESTS

Authors have declared that no competing interests exist.

REFERENCES

1. Waldvogel FA, Medoff G, Swartz MN. Osteomyelitis: A Review of Clinical Features, Therapeutic Considerations and Unusual Aspects [Internet]. *New England Journal of Medicine*. 1970;282:260–6. Available: <http://dx.doi.org/10.1056/nejm197001292820507>
2. Yamunadevi A, Pratibha R, Rajmohan M, Ganapathy N, Porkodisudha J, Pavithrah D, et al. Molecular insight into odontogenesis in hyperglycemic environment: A systematic review [Internet]. *Journal of Pharmacy And Bioallied Sciences*. 2020;12:49. Available: http://dx.doi.org/10.4103/jpbs.jpbs_159_20
3. Lieblich SE, Piecuch JF. Infections of the Jaws, Including Infected Fractures, Osteomyelitis, and Osteoradionecrosis [Internet]. *Atlas of the Oral and Maxillofacial Surgery Clinics*. 2000;8:121–32. Available: [http://dx.doi.org/10.1016/s1061-3315\(18\)30045-3](http://dx.doi.org/10.1016/s1061-3315(18)30045-3)
4. Sukumaran G, Ramani P, Ramasubramanian A, Karunagaran M, Ravikumar H. Implantation Dermoid Cyst [Internet]. *Journal of Evolution of Medical and Dental Sciences*. 2019;8:4023–5. Available: <http://dx.doi.org/10.14260/jemds/2019/871>
5. Sinduja P, Ramani P, Gheena S, Ramasubramanian A. Expression of metallothionein in oral squamous cell carcinoma: A systematic review [Internet]. *Journal of Oral and Maxillofacial Pathology*. 2020;24:143. Available: http://dx.doi.org/10.4103/jomfp.jomfp_137_19

6. Taher AAY. Osteomyelitis of the mandible in Tehran, Iran [Internet]. *Oral Surgery, Oral Medicine, Oral Pathology*. 1993;76:28–31. Available: [http://dx.doi.org/10.1016/0030-4220\(93\)90288-f](http://dx.doi.org/10.1016/0030-4220(93)90288-f)
7. Association of the Depth of Invasion with Lymph Node Metastasis in Oral Squamous Cell Carcinoma Patients - A Retrospective Study [Internet]. *Indian Journal of Forensic Medicine & Toxicology*; 2020. Available:<http://dx.doi.org/10.37506/ijfmt.v14i4.12542>
8. Wang R, Cai Y, Zhao YF, Zhao JH. Osteomyelitis of the condyle secondary to pericoronitis of a third molar: a case and literature review. *Aust Dent J*. 2014;59(3):372–4.
9. Sathyavathy K, Madhusudhan BK. Review on Clinical Diseases Caused by Klebsiella”, *Journal of Pharmaceutical Research International*. 2020;32(21):12-19. DOI: 10.9734/jpri/2020/v32i2130745.
10. Baltensperger M, Eyrich G. Osteomyelitis of the Jaws: Definition and Classification [Internet]. *Osteomyelitis of the Jaws*: 5–56. Available: http://dx.doi.org/10.1007/978-3-540-28766-7_2
11. Umashankar K, RA, RH, Ramani P, SG. Knowledge and Attitude About COVID-19 Pathogenesis Among Oral Pathologists in Chennai [Internet]. *International Journal of Current Research and Review*. 2020;12:143–51. Available:<http://dx.doi.org/10.31782/ijcrr.2020.sp17>
12. Eckardt JJ, Wirganowicz PZ, Mar T. An aggressive surgical approach to the management of chronic osteomyelitis. *Clin Orthop Relat Res*. 1994;(298):229–39.
13. Balanger M, Hinet M, Vacher C, Bellaiche N, Charrier J-L, Millot S. Osteomyelitis of the Mandible after Dental Implants in an Immunocompetent Patient [Internet]. *Case Reports in Dentistry*. 2017:1–5. Available:<http://dx.doi.org/10.1155/2017/9525893>
14. Figueiredo LMG, Castro Trindade S, Sarmiento VA, de Oliveira TFL, Muniz WR, de Hollanda Valente RO. Actinomycotic osteomyelitis of the mandible: an unusual case [Internet]. *Oral and Maxillofacial Surgery*. 2013;17:299–302. Available:<http://dx.doi.org/10.1007/s10006-012-0381-2>
15. Analysis of Prevalence of Oral Squamous Cell Carcinoma in Patients with History of Chronic Irritation of Oral Tissues - A Retrospective Study [Internet]. *Indian Journal of Forensic Medicine & Toxicology*. 2020. Available:<http://dx.doi.org/10.37506/ijfmt.v14i4.12511>
16. Gupta D, Sheikh S, Pallagatti S. Osteomyelitis of Jaws vs. Long Bones [Internet]. *Comprehensive Maxillofacial Osteomyelitis*. 2018:73–5. Available:<http://dx.doi.org/10.2174/9781681086231118010010>
17. A study on the variability of drug responsiveness to anti inflammatory drugs - A pilot survey [Internet]. *International Journal of Pharmaceutical Research*. 2020;12. Available:<http://dx.doi.org/10.31838/ijpr/2020.12.02.0261>
18. Daramola JO, Ajagbe HA. Chronic osteomyelitis of the mandible in adults: A clinical study of 34 cases [Internet]. *British Journal of Oral Surgery*. 1982;20:58–62. Available: [http://dx.doi.org/10.1016/0007-117x\(82\)90008-7](http://dx.doi.org/10.1016/0007-117x(82)90008-7)
19. Kremers HM, Nwojo ME, Ransom JE, Wood-Wentz CM, Joseph Melton L, Huddleston PM. Trends in the Epidemiology of Osteomyelitis [Internet]. *Journal of Bone and Joint Surgery*. 2015;97:837–45. Available:<http://dx.doi.org/10.2106/jbjs.n.01350>
20. Koorbusch GF, Fotos P, Goll KT. Retrospective assessment of osteomyelitis [Internet]. *Oral Surgery, Oral Medicine, Oral Pathology*. 1992;74:149–54. Available: [http://dx.doi.org/10.1016/0030-4220\(92\)90373-x](http://dx.doi.org/10.1016/0030-4220(92)90373-x)
21. Prasad >kishore Chandra, Prasad SC, Mouli N, Agarwal S. Osteomyelitis in the head and neck [Internet]. *Acta Oto-Laryngologica*. 2007;127:194–205. Available:<http://dx.doi.org/10.1080/00016480600818054>
22. Thamilselvan S, Abilasha R, Ramani P, Gheena S, Hannah R. Evaluation of Accuracy between Habit History and Incidence of Oral Squamous Cell Carcinoma [Internet]. *International Journal of Current Research and Review*. 2020:30–5. Available:<http://dx.doi.org/10.31782/ijcrr.2020.122503>
23. Hao S-P, Chen HC, Wei F-C, Chen C-Y, Yeh AR-M, Su J-L. Systematic Management of Osteoradionecrosis in the

- Head and Neck [Internet]. The Laryngoscope. 1999;109:1324–7. Available: <http://dx.doi.org/10.1097/00005537-199908000-00027>
24. Ramani P, Krishnan R, Karunagaran M, Muthusekhar MR. Odontogenic sarcoma: First report after new who nomenclature with systematic review [Internet]. Journal of Oral and Maxillofacial Pathology. 2020;24:157. Available: http://dx.doi.org/10.4103/jomfp.jomfp_14_20
 25. Masthan KMK. Diseases of the Pulp and Periapical Tissues [Internet]. Textbook of Pediatric Oral Pathology. 2011:13–13. Available: http://dx.doi.org/10.5005/jp/books/11365_2
 26. Arani R, Afsar Shareef SN, Khuthija Khanam HM. Mucormycotic Osteomyelitis Involving the Maxilla: A Rare Case Report and Review of the Literature [Internet]. Vol. 2019, Case Reports in Infectious Diseases. 2019:1–6. Available: <http://dx.doi.org/10.1155/2019/8459296>
 27. Schuknecht B, Valavanis A. Osteomyelitis of the mandible [Internet]. Neuroimaging Clinics of North America. 2003;13:605–18. Available: [http://dx.doi.org/10.1016/s1052-5149\(03\)00044-3](http://dx.doi.org/10.1016/s1052-5149(03)00044-3)
 28. Ramasubramanian A, Ramani P, Sherlin H, Premkumar P, Natesan A, Thiruvengadam C. Immunohistochemical evaluation of oral epithelial dysplasia using cyclin-D1, p27 and p63 expression as predictors of malignant transformation [Internet]. Journal of Natural Science, Biology and Medicine. 2013;4:349. Available: <http://dx.doi.org/10.4103/0976-9668.117011>
 29. Wurman LH, Flannery JV, Garry Sack J. Osteomyelitis of The Mandibular Condyle Secondary to Dental Extractions [Internet]. Otolaryngology–Head and Neck Surgery. 1979;87:190–8. Available: <http://dx.doi.org/10.1177/019459987908700207>
 30. Kaneda T, Yamamoto H, Suzuki H, Ozawa M. A clinoradiological study of maxillary osteomyelitis [Internet]. The Journal of Nihon University School of Dentistry. 1989;31:464–9. Available: <http://dx.doi.org/10.2334/josnurd1959.31.464>
 31. Nezafati S, Ghavimi MA, Yavari AS. Localized osteomyelitis of the mandible secondary to dental treatment: report of a case. Journal of Dental Research, Dental Clinics, Dental Prospects. 2009;3(2):67.
 32. Schulze D, Blessmann M, Pohlenz P, Wagner KW, Heiland M. Diagnostic criteria for the detection of mandibular osteomyelitis using cone-beam computed tomography [Internet]. Dentomaxillofacial Radiology. 2006;35:232–5. Available: <http://dx.doi.org/10.1259/dmfr/71331738>

© 2021 Akshayaa and Ramani; This is an Open Access article distributed under the terms of the Creative Commons Attribution License (<http://creativecommons.org/licenses/by/4.0>), which permits unrestricted use, distribution, and reproduction in any medium, provided the original work is properly cited.

Peer-review history:
The peer review history for this paper can be accessed here:
<https://www.sdiarticle5.com/review-history/81723>